

## Concise report

# Monitoring Achilles enthesitis in ankylosing spondylitis during TNF- $\alpha$ antagonist therapy: an ultrasound study

Sibel Zehra Aydin<sup>1</sup>, Omer Karadag<sup>2</sup>, Emilio Filippucci<sup>3</sup>, Pamir Atagunduz<sup>1</sup>, Ali Akdogan<sup>2</sup>, Umut Kalyoncu<sup>2</sup>, Walter Grassi<sup>3</sup> and Haner Direskeneli<sup>1</sup>

## Abstract

**Objective.** Enthesitis is considered as the primary anatomical lesion in ankylosing spondylitis (AS). Therapeutic effects of TNF- $\alpha$  antagonist treatments for enthesitis on imaging changes are still limited to case reports or small sample-sized trials. We aimed to investigate the potential of ultrasonography (US) to detect early changes after TNF- $\alpha$  antagonist therapy of Achilles enthesitis of AS patients.

**Methods.** Forty-three AS patients with active disease, requiring TNF- $\alpha$  antagonist therapy, were included. Physical examination was performed to detect Achilles enthesitis and/or retrocalcaneal bursitis. US of the Achilles tendon was performed bilaterally. Grey-scale (GS) and power Doppler (PD) scores on a 0–2 semi-quantitative scale and total additive scores (TS) were calculated. Follow-up US examinations were performed 2 months after the initiation of therapy.

**Results.** At baseline, 11 patients (26.2%) were symptomatic in physical examination for either Achilles enthesitis or retrocalcaneal bursitis, whereas 36 (83%) had GS US pathological findings and 10 (23.3%) had PD signal. GS score and TS decreased significantly [3.6 (3.0) vs 2.3 (2.2),  $P < 0.001$  and 4.7 (4.9) vs 2.7 (3.3),  $P < 0.001$ , respectively], whereas the decrease in PD score was not significant after 2 months of follow-up. The Bath Ankylosing Spondylitis Disease Activity Index (BASDAI), ESR and CRP levels also showed significant improvements.

**Conclusions.** Subclinical Achilles enthesitis, detected only with GS US, is present in a subset of AS patients and a significant improvement can be demonstrated after 2 months of TNF- $\alpha$  antagonist therapy. In addition to standard outcome measures, US might be an additional useful tool to monitor therapy in SpA patients with Achilles enthesitis.

**Key words:** Ultrasonography, Enthesitis, Achilles tendon, Ankylosing spondylitis, TNF- $\alpha$  antagonist therapy.

## Introduction

Enthesitis is the inflammation of ligaments, tendons or joint capsules at the point of their insertion into the bone, and is considered a predominant feature of SpAs [1, 2]. Disability in SpAs is generally due to spinal enthesal, new bone formation [3]. Despite its clinical importance, treatment options for enthesitis are limited.

Therapy is usually conservative, including NSAIDs, orthoses and local steroid injections [4]. TNF- $\alpha$  antagonists have been tried in refractory cases, but the level of evidence for their effects on enthesitis, especially documented by imaging, is limited. There are case presentations using ultrasonography (US) that report decreased vascularity by TNF- $\alpha$  antagonists [5] and small sample-sized trials demonstrating the response of spinal inflammation by MRI [6]. In other studies investigating the effects of TNF- $\alpha$  antagonists on ankylosing spondylitis, enthesitis detected by clinical examination also responded well in subgroup analysis [7, 8].

Physical examination can be inadequate for diagnosing enthesitis [9, 10], whereas US is a sensitive, non-invasive, rapid and inexpensive tool for this purpose [9–11]. US has already been proved to be helpful in monitoring synovitis,

<sup>1</sup>Rheumatology, Marmara University, School of Medicine, Istanbul,

<sup>2</sup>Rheumatology, Hacettepe University Hospital, Ankara, Turkey,

<sup>3</sup>Clinica Reumatologica, Università Politecnica delle Marche, Ancona, Italy.

Submitted 19 May 2009; revised version accepted 5 November 2009.

Correspondence to: Sibel Zehra Aydin, Marmara University Hospital, Rheumatology Department, Tophanelioglu cad. 13/15, 34662 Altunizade, Istanbul, Turkey. E-mail: drsibelaydin@gmail.com

detecting early changes induced by TNF- $\alpha$  antagonist therapy in patients with RA [12, 13]. In the present study, we aimed to investigate the role of US in detecting early changes and response to TNF- $\alpha$  antagonists of Achilles enthesitis of AS patients.

## Methods

### Patients

Forty-three AS patients fulfilling Modified 1984 New York criteria [14] from two university hospital rheumatology clinics (Marmara University Hospital, Istanbul and Hacettepe University Hospital, Ankara, Turkey) were involved in the study. All AS patients had active axial and/or peripheral involvement and Bath Ankylosing Spondylitis Disease Activity Index (BASDAI) scores  $\geq 4$  which required treatment with TNF- $\alpha$  antagonists in standard doses (infliximab  $n=17$ , etanercept  $n=17$ , adalimumab  $n=9$ ). Patients with a history of malignancy, active tuberculosis, women in pregnancy or lactation; patients who had previous injection or surgical procedures to the Achilles tendon (AT) or were receiving high-dose steroids ( $>10$  mg prednisolone) were excluded. Therapies other than TNF- $\alpha$  antagonists were kept stable during the study period (SSZ 74.4%, MTX 44.2%, prednisolone 5%). All patients received NSAIDs at the beginning and continued on demand. Disease activity was assessed by BASDAI; ESR and CRP level were also recorded. The physical examination of the each AT and deep retrocalcaneal bursa was performed by an experienced rheumatologist, determining both tenderness and swelling. The study was approved by the Ethical Committee of Marmara University Medical School and informed consent was obtained from all patients.

### US scanning technique

The US examinations were performed in a darkened room by two rheumatologists (S.Z.A. and O.K.), one for each centre, blinded to clinical data and patients' identity, using a MyLab 70 (Esaote Biomedica, Genoa, Italy), equipped with a broadband 6–18 MHz linear probe. Power Doppler (PD) settings were standardized with a pulse repetition frequency of 750 Hz, a colour-mode frequency of 9.1 MHz and low wall filters. The colour gain was increased to the highest value not generating PD signals under the bony cortex [15, 16]. The patients were asked to take a prone position, with the feet hanging off the examination table in a neutral position for visualization of the AT [17–20]. Bilateral AT US examinations were carried out using a multiplanar scanning technique. Particular attention was paid not to apply transducer pressure on the anatomical structures under examination.

The follow-up US examinations were performed 2 months after starting TNF antagonist therapy by the same investigators in both centres using the same US machine, same setting parameters and scanning technique as the previous one.

### US images interpretation

The OMERACT [21] preliminary definition of enthesopathy was adopted for detecting US findings indicative of Achilles enthesitis. As the study is short term and US findings indicating damage like bone profile changes and calcifications are not expected to change within this period, only US findings reflecting inflammation were included in the final scores [17–22]. Semi-quantitative US assessment was carried out according to a scoring system recently developed for rating Achilles enthesitis [23].

The three calculated scores for each patient and used parameters were:

- (i) A PD score indicating vascularity at three levels (tendon, bursa and enthesitis), ranging from 0 to 12 with semi-quantitative scores (per patient).
- (ii) A GS score: the thickness and hypoechogenicity of enthesitis and tendon, presence of retrocalcaneal bursitis indicated by effusion, ranging from 0 to 16 with semi-quantitative scores (per patient).
- (iii) A total score: the sum of PD and GS scores, ranging from 0 to 28 with semi-quantitative scores (per patient).

### Statistical analysis

The inter-observer agreement for US evaluation of the AT enthesitis was tested on 28 SpA patients prior to the current study and the results showed good level of agreement ( $\kappa = 0.647$ ). The intra-observer agreement was tested by re-scoring the stored images by one of the sonographers (S.Z.A.) in 14 SpA patients and an excellent level of agreement ( $\kappa = 0.816$ ) was obtained [23].

Sensitivity to change of US scores was estimated by the smallest detectable difference (SDD). The mean ( $d_{\text{mean}}$ ) and s.d. of the paired differences within reader (intra-reader scores) were calculated. SDD was determined according to the Bland–Altman 95% limits of agreement method where 95% limits are  $d_{\text{mean}}$  (1.96 s.d.) [24, 25].

For comparison of BASDAI, ESR, CRP, GS score, PD score and total score between the time points, the Wilcoxon test was used. Patients with or without clinical enthesitis were compared for GS score, PD score and total score with the Mann–Whitney U-test. Correlations of US scores and other disease activity markers were analysed by Pearson correlation test. Also, the difference in US scores for three TNF- $\alpha$  antagonist drugs (infliximab, adalimumab and etanercept) was investigated by Kruskal–Wallis test followed by Mann–Whitney U-test within groups. All tests were performed using version 13.0 of SPSS software for Windows (SPSS, Chicago, IL, USA).

## Results

### Patients

The mean age of AS patients was 35.4 (12.5) years. Twenty-six of 43 patients (60.5%) were males. Eleven

patients (26.2%) had enthesitis or bursitis on clinical examination. Seventy-six per cent of patients required TNF- $\alpha$  antagonist therapy for axial disease, 5% for peripheral disease and the remaining 19% for both axial and peripheral disease.

### Clinical findings

Baseline and follow-up values of BASDAI, ESR and CRP are given in Table 1. A significant decrease in clinical and laboratory findings indicative of inflammation was found 2 months after the beginning of the anti-TNF therapy. Six of 43 patients (14%) had a BASDAI >4 after 2 months. Four of these patients were receiving etanercept, one adalimumab and one infliximab. Among the 11 patients who initially had Achilles enthesitis and/or retrocalcaneal bursitis on clinical examination, four of them had the same physical examination findings at follow-up.

### US findings

At baseline, at least one pathological GS finding was observed in 83% of patients while in only 23.3% of patients the PD signal was detected either in enthesitis, tendon or bursa. All GS scores, PD scores and total scores for AT decreased after the second month following TNF- $\alpha$  antagonist therapy (Table 1). The decrease in GS scores and total scores were significant despite a lack of significance in PD scores. The SDD was 0.9 for GS score, 0 for PD score and 0.9 for TS. The number of patients whose decrease in US scores was higher than SDD was 24/43 (56%) for GS, 7/43 (16%) for PD and 25/43 (58%).

When the components of US findings indicating enthesitis were analysed separately, a decrease in hypo-echogenicity was observed in 18.6% of the tendons and 31.4% of the enthesitis. In 25% of patients, the bursal enlargement also decreased after 2 months of therapy. However, only in two ATs (2.3%), did the score for the thickness of the tendon decrease. Seven of 10 patients (70%) with initial PD signal had a decrease in PD score, while the PD score of one patient increased and two remained unchanged after therapy (Fig. 1). The BASDAI levels of the remaining three patients decreased to a level <2. The ESR was high (40 mm/h) in one these patients which also decreased to 11 mm/h with therapy. All three

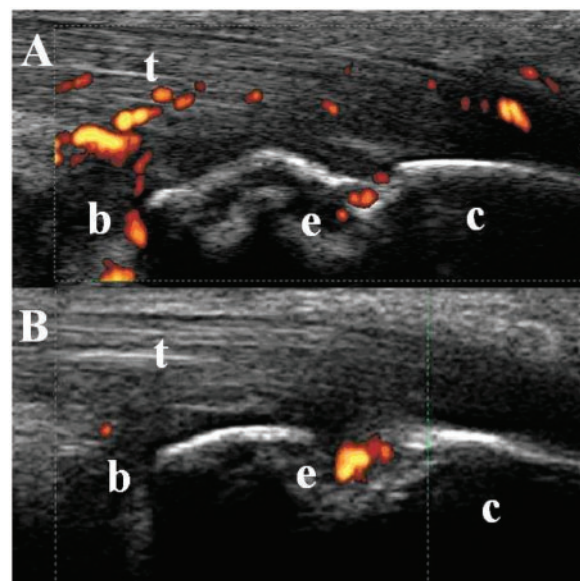
patients had normal CRP levels before and after treatment.

### Correlation between clinical and US findings

BASDAI, ESR and CRP levels were similar in groups with or without symptomatic enthesitis or bursitis, whereas the GS score, PD score and total score were significantly higher in symptomatic patients [GS score: 6.6 (2.7) vs 2.7 (2.5),  $P < 0.001$ ; PD score: 3.6 (3.6) vs 0.1 (0.4),  $P = 0.003$ ; total score: 10.2 (5.7) vs 2.8 (2.7),  $P < 0.001$ ]. Follow-up US scores were also significantly higher in symptomatic than in asymptomatic patients [GS score: 4.7 (1.9) vs 1.4 (1.5),  $P < 0.001$ ; PD score: 1.9 (2.8) vs 0 (0),  $P = 0.076$ ; total score: 6.6 (4.0) vs 1.4 (1.5),  $P < 0.001$ ]. The decrease associated with therapy was not significantly different and was dependent on the presence of clinically detected enthesitis [total score: 3.7 (5.5) in the symptomatic group vs 1.7 (1.8) in the asymptomatic group,  $P = \text{NS}$ ].

Reduction in GS score correlated with CRP changes (Spearman's  $r^2 = 0.565$ ,  $P = 0.002$ ), whereas no significant correlation was observed between GS score reduction and ESR or BASDAI. PD score reduction correlated with ESR reduction ( $r^2 = 0.413$ ,  $P = 0.032$ ); however, there was no relation to other clinical activity markers. The improvement in TS significantly correlated with improvement in CRP levels ( $r^2 = 0.679$ ,  $P < 0.001$ ), had a tendency to correlate with improvement in ESR ( $r^2 = 0.367$ ,  $P = 0.059$ ), but was independent of the changes in BASDAI ( $r^2 = -0.121$ ,  $P = 0.52$ ).

**Fig 1** AS. Representative sonographic images acquired in longitudinal scan at baseline (A) and after 2 months of therapy (B). At follow-up, US examination showed a clearly evident decrease in PD signal at both AT (t) and retrocalcaneal bursa (b) levels and the persistence of PD signal within the bone erosion (e). c: calcaneus.



**Table 1** Baseline and follow-up mean values (s.d.) of clinical and US findings

Scores	Baseline	Follow-up	SDD	P-value*
BASDAI	5.6 (1.8)	2 (1.4)		<0.001
ESR, mm/h	39.5 (25.4)	11.2 (9.1)		<0.001
CRP, mg/l	19.4 (33.8)	2.6 (5.6)		<0.001
GS score	3.6 (3.0)	2.3 (2.2)	0.9	<0.001
PD score	1.0 (2.4)	0.5 (1.6)	0	0.067
Total US score	4.7 (4.9)	2.7 (3.3)	0.9	<0.001

\*Before and after treatment comparisons were performed by Wilcoxon test.

Analysing the gender, despite the similar initial BASDAI, ESR and CRP level, men had significantly higher baseline GS, PD and total scores [GS of men: 4.73 (2.80) vs women: 1.94 (2.66),  $P=0.001$ ; PD of men: 1.46 (2.73) vs women: 0.35 (1.46),  $P=0.04$ ; total score of men: 6.19 (4.82) vs women: 2.29 (4.0),  $P<0.001$ ]. Follow-up GS and total scores for men were also higher, whereas PD score was similar for both genders. The differences gained by treatment in all US scores were also similar for both genders (data not given).

When three different TNF- $\alpha$  antagonists were analysed separately, similar response rates were observed in GS, PD and total scores.

## Discussion

Over the last few years, a number of investigations have been carried out to assess the ability of US to detect synovial changes induced by TNF- $\alpha$  antagonist therapy in patients with RA [12, 13, 15]. The sensitivity of change in US findings indicating enthesitis in SpA was less studied. Two studies on SpA patients treated with SSZ were not able to find any difference in 6–12 months, which may also be due to the ineffectiveness of the therapy [26, 27]. One case report demonstrated the healing process in Achilles enthesitis with infliximab therapy using US [5]. To our knowledge, this is the first study aiming to evaluate the value of US in short-term monitoring of Achilles enthesitis in AS patients under TNF- $\alpha$  antagonist therapy.

Although only one-quarter of AS patients in our study group had clinical enthesitis or bursitis, most of them had US signs indicating inflammation, which significantly improved after 2 months of therapy. The reversibility of US findings by an effective treatment emphasize that imaging can help close monitoring of enthesitis in AS patients before a clinical response is observed.

Patients with clinical signs of enthesitis or bursitis had higher GS, PD and TS, whereas their BASDAI, ESR and CRP level were similar compared with patients without any clinical findings. In general, BASDAI is used as a marker of disease activity, and ESR and CRP levels usually reflect inflammation as well, but none of them seem to have a concordance with enthesitis in our study. Only US findings had a high concordance with enthesitis, suggesting that US might be a major follow-up method in SpA patients with enthesitis.

Doppler US is a sensitive method for assessing blood flow and provides a reliable estimation of soft tissue inflammation [28, 29]. Approximately one-quarter of our patients had initial PD signal and within this group there was a response rate of 70% in PD scores after therapy. However, the number of patients in our group with positive PD score was possibly insufficient to detect a significant difference. The good reproducibility of PD in enthesitis, which our group has previously demonstrated and the high response rates detected in the current study indicate that PD can be a promising tool to follow up enthesitis in clinical trials and needs further research with a higher number of patients [23].

The prognosis of AS in men is generally worse than in women [30, 31]. We have also previously observed that both genders have the same disease activity (assessed with BASDAI), whereas men have worse radiographic scores as shown by Bath ankylosing spondylitis Radiology Index and modified Stoke ankylosing spondylitis spine score [32]. Similar to this observation, in the current study, men and women were found to have similar disease activity but enthesitis scores detected by US in men were significantly higher. The explanation of a worse functional and radiographic outcome in men, despite having similar clinical characteristics and disease activity markers in AS, may be the effect of an increased prevalence of underdiagnosed enthesitis. The current methods used to assess the disease activity in SpAs mainly aim to evaluate axial involvement and are not sensitive enough to determine the extent and severity of the enthesitis and our findings require further research with the aim of demonstrating the enthesitis of the axial system better.

The main limitation of our study is its open, uncontrolled design and short follow-up. However, a controlled study of enthesitis in SpAs is difficult to perform as TNF- $\alpha$  antagonists are mainly indicated for axial disease with BASDAI as the primary outcome. Evaluation of a mixed group of patients using different TNF- $\alpha$  antagonists can also be criticized; however, no significant therapeutic differences are reported in axial or peripheral disease in AS among different TNF $\alpha$  antagonists.

In conclusion, TNF- $\alpha$  antagonists have been shown to be effective in decreasing US signs of enthesitis after only 2 months of therapy in AS patients. As BASDAI and acute phase reactant levels were not discriminative for symptomatic and asymptomatic enthesitis, US might be a more useful tool to monitor clinical responses associated with enthesitic features in SpA patients.

### Rheumatology key message

- Ultrasound is a useful tool for monitoring the therapeutic response to TNF antagonists in SpA patients with Achilles enthesitis.

*Disclosure statement:* The authors have declared no conflicts of interest.

## References

- 1 Routhy MK, Schweitzer M, Resnick D, Enthesopathy. In: Klippel JH, Dieppe PA, eds, Rheumatology. 2nd edition. London: Times-Mirror International Publishers, 1998. 6.13.1–6.13.2.
- 2 Ball J. Enthesopathy of rheumatoid and ankylosing spondylitis. *Ann Rheum Dis* 1971;30:213–23.
- 3 McGonagle D. Diagnosis and treatment of enthesitis. *Rheum Dis Clin North Am* 2003;29:549–60.
- 4 Dougados M, Revel M, Khan MA. Spondylarthropathy treatment: progress in medical treatment, physical therapy and rehabilitation. *Baillieres Clin Rheumatol* 1998;12: 717–36.

- 5 D'Agostino MA, Breban M, Said-Nahal R, Dougados M. Refractory inflammatory heel pain in spondylarthropathy: a significant response to infliximab documented by ultrasound. *Arthritis Rheum* 2002;46:840–1.
- 6 Marzo-Ortega H, McGonagle D, O'Connor P, Emery P. Efficacy of etanercept in the treatment of the enthesal pathology in resistant spondylarthropathy: a clinical and magnetic resonance imaging study. *Arthritis Rheum* 2001;44:2112–7.
- 7 Braun J, Brandt J, Listing J *et al.* Treatment of active ankylosing spondylitis with infliximab: a randomised controlled multicentre trial. *Lancet* 2002;359:1187–93.
- 8 Gorman JD, Sack KE, Davis JC Jr. Treatment of ankylosing spondylitis by inhibition of tumor necrosis factor alpha. *N Engl J Med* 2002;346:1349–56.
- 9 Balint PV, Kane D, Wilson H, McInnes IB, Sturrock RD. Ultrasonography of enthesal insertions in the lower limb in spondyloarthropathy. *Ann Rheum Dis* 2002;61:905–10.
- 10 Fournié B, Margarit-Coll N, Champetier de Ribes TL *et al.* Extrasynovial ultrasound abnormalities in the psoriatic finger. Prospective comparative power-Doppler study versus rheumatoid arthritis. *Joint Bone Spine* 2006;73:527–31.
- 11 Grassi W, Salaffi F, Filippucci E. Ultrasound in rheumatology. *Best Pract Res Clin Rheumatol* 2005;19:467–85.
- 12 Iagnocco A, Filippucci E, Perella C *et al.* Clinical and ultrasonographic monitoring of response to adalimumab treatment in rheumatoid arthritis. *J Rheumatol* 2008;35:35–40.
- 13 Naredo E, Möller I, Cruz A, Carmona L, Garrido J. Power Doppler ultrasonographic monitoring of response to anti-tumor necrosis factor therapy in patients with rheumatoid arthritis. *Arthritis Rheum* 2008;58:2248–56.
- 14 van der Linden S, Valkenburg HA, Cats A. Evaluation of diagnostic criteria for ankylosing spondylitis. A proposal for modification of the New York criteria. *Arthritis Rheum* 1984;27:361–8.
- 15 Filippucci E, Iagnocco A, Salaffi F, Cerioni A, Valesini G, Grassi W. Power Doppler sonography monitoring of synovial perfusion at the wrist joints in patients with rheumatoid arthritis treated with adalimumab. *Ann Rheum Dis* 2006;65:1433–7.
- 16 Torp-Pedersen ST, Terslev L. Settings and artefacts relevant in colour/power Doppler ultrasound in rheumatology. *Ann Rheum Dis* 2008;67:143–9.
- 17 D'Agostino MA, Said-Nahal R, Hacquard-Bouder C *et al.* Assessment of peripheral enthesitis in the spondyloarthropathies by ultrasonography combined with power Doppler: a cross-sectional study. *Arthritis Rheum* 2003;48:523–33.
- 18 Balint PV, Kane D, Wilson H, McInnes IB, Sturrock RD. The majority of lower limbs enthesopathy in seronegative spondyloarthropathy is underestimated by clinical examination: an ultrasonographic study [abstract]. *Arthritis Rheum* 2001;44:S93.
- 19 Backhaus M, Burmester G-R, Gerber T *et al.* Guidelines for musculoskeletal ultrasound in rheumatology. *Ann Rheum Dis* 2001;60:641–9.
- 20 Riente L, Delle Sedie A, Filippucci E *et al.* Ultrasound imaging for the rheumatologist. IX. Ultrasound imaging in spondyloarthritis. *Clin Exp Rheumatol* 2007;25:349–53.
- 21 Wakefield RJ, Balint PV, Szkudlarek M *et al.* Musculoskeletal ultrasound including definitions for ultrasonographic pathology. *J Rheumatol* 2005;32:2485–7.
- 22 Alcalde M, Acebes JC, Cruz M, González-Hombrado L, Herrero-Beaumont G, Sánchez-Pernaute O. A sonographic enthesitic index of lower limbs is a valuable tool in the assessment of ankylosing spondylitis. *Ann Rheum Dis* 2007;66:1015–9.
- 23 Filippucci E, Aydin SZ, Karadag O *et al.* Reliability of high-resolution ultrasonography in the assessment of Achilles tendon enthesopathy in seronegative spondyloarthropathies. *Ann Rheum Dis* 2009;68:1850–5.
- 24 Bland JM, Altman DG. Statistical methods for assessing agreement between two methods of clinical measurement. *Lancet* 1986;1:307–10.
- 25 Bland JM, Altman DG. Comparing two methods of clinical measurement: a personal history. *Int J Epidemiol* 1995;24(Suppl. 1):S7–14.
- 26 Lehtinen A, Leirisalo-Repo M, Taavitsainen M. Persistence of enthesopathic changes in patients with spondylarthropathy during a 6-month follow-up. *Clin Exp Rheumatol* 1995;13:733–6.
- 27 Genc H, Duyur Cakit B, Nacir B, Saracoglu M, Kacar M, Erdem HR. The effects of sulfasalazine treatment on enthesal abnormalities of inflammatory rheumatic diseases. *Clin Rheumatol* 2007;26:1104–10.
- 28 Newman JS, Adler RS, Bude RO, Rubin JM. Detection of soft-tissue hyperemia: value of power Doppler sonography. *AJR Am J Roentgenol* 1994;153:385–9.
- 29 Schmidt WA, Völker L, Zacher J, Schläfke M, Ruhnke M, Gromnica-Ihle E. Colour Doppler ultrasonography to detect pannus in knee-joint synovitis. *Clin Exp Rheumatol* 2000;18:439–44.
- 30 Braunstein EM, Martel W, Moidel R. Ankylosing spondylitis in men and women: a clinical and radiographic comparison. *Radiology* 1982;144:91–4.
- 31 Jimenez-Balderas FJ, Mintz G. Ankylosing spondylitis: clinical course in women and men. *J Rheumatol* 1993;20:2069–72.
- 32 Atagunduz P, Aydin S, Ozturk MA, Kocakaya O, Direskeneli H. The relationship of clinical features and laboratory measurements to radiological damage in a Turkish cohort of patients with ankylosing spondylitis: a cross sectional study. Abstract 1173. *Arthritis Rheum* 2007;56.