

Primary Subcutaneous Hydatid Cyst Over Thoracic Spine: A Case Report and Review of the Literature

Torakal Omurga Yerleşimli Primer Cilt Altı Hidatik Kist: Bir Olgu Sunumu ve Literatürün Gözden Geçirilmesi

Murat Şakir Ekşi¹, Yaşar Bayrı¹, Ayten Saraçoğlu², Süheyla Uyar Bozkurt³, Deniz Konya¹

¹Department of Neurosurgery, Faculty of Medicine, Marmara University, İstanbul, Turkey

²Department of Anesthesiology, Faculty of Medicine, Marmara University, İstanbul, Turkey

³Department of Pathology, Faculty of Medicine, Marmara University, İstanbul, Turkey

ABSTRACT

Hydatid disease is a public health problem in endemic areas. Although it is most commonly present in the liver and lung, it rarely affects other tissues. A 62-year-old female patient was admitted to our outpatient clinic with a palpable, moderately mobile mass over the thoracic spine. On MRI, a cystic lesion, hypointense and hyperintense on T1- and T2-weighted scans, respectively, was detected. During surgery, a well capsulated cyst was excised en bloc. On histological examination, a hydatid cyst was diagnosed. Her postoperative serological test was positive. Her whole body was scanned for any other organ involvement, but scans were all negative. She was treated with albendazol. After 3 months, the test result was negative, and there were no local or systemic recurrences. Primary subcutaneous tissue involvement is a rarely reported entity in the literature. To the best of our knowledge, this is the first case report of a primary subcutaneous hydatid cyst detected over the thoracic spine. (*Türkiye Parazitolojisi Dergisi* 2014; 38: 264-9)

Keywords: Echinococcus, hydatid cyst, magnetic resonance imaging, surgery

Received: 21.05.2013

Accepted: 11.06.2014

ÖZET

Hidatik hastalığı, endemik bölgelerde halk sağlığı problemi oluşturmaktadır. En sık karaciğer ve akciğerde tespit edilmekle beraber, nadir de olsa diğer dokuları da etkileyebilir. Altmış iki yaşında kadın hasta, torakal omurgası üzerinde ele gelen, hareketli kitle ile kliniğimize başvurdu. Manyetik rezonans görüntülemesinde, T1-ağırlıklı incelemede hipointens, T2-ağırlıklı incelemede hiperintens olan kistik bir kitle tespit edildi. Ameliyat kararı verilen hastanın cerrahisinde, ciltaltı yerleşimli kapsüllü yapıda bir kist en-blok çıkarıldı. Histolojik incelemede sonuç hidatik kist olarak bildirildi. Post-op bakılan ekinokok serolojisi pozitif. Hastanın bütün vücudu olası diğer odaklar için tarandı; fakat sonuç negatifti. Üç ay boyunca albendazol tedavisi gören hastanın test sonuçları negatif geldi. Yerel veya sistemik hastalık tekrarı saptanmadı. Ciltaltı hidatik kist nadir bir klinik durumdur. Literatür taramamıza göre bu olgu torakal omurga üzerinde saptanan ilk primer cilt altı hidatik kist olgusudur. (*Türkiye Parazitolojisi Dergisi* 2014; 38: 264-9)

Anahtar Sözcükler: Ekinokok, hidatik kist, manyetik rezonans görüntüleme, cerrahi

Geliş Tarihi: 21.05.2013

Kabul Tarihi: 11.06.2014

Address for Correspondence / Yazışma Adresi: Dr. Murat Şakir Ekşi, Department of Neurosurgery, Faculty of Medicine, Marmara University, İstanbul, Turkey. Phone: +1 415 734 70 63 E-mail: muratsakireksi@gmail.com
DOI: 10.5152/tpd.2014.3198

©Copyright 2014 Turkish Society for Parasitology - Available online at www.tparazitolog.org

©Telif hakkı 2014 Türkiye Parazitoloji Derneği - Makale metnine www.tparazitolog.org web sayfasından ulaşılabilir.

INTRODUCTION

Human hydatid disease is caused by infection with the larval stage of taeniid cestodes of *Echinococcus* (1-3). There are six known species, as follows: *E. granulosus* (cystic echinococcosis), *E. multilocularis* (alveolar echinococcosis), *E. vogeli*, and *E. oligarthrus* (polycystic echinococcosis), but four species are a public health concern (1-3). *E. granulosus* is the most frequent cause of the disease (4). It is a public health problem in endemic areas (temperate zones such as Central Asia, China, Central and Southern parts of former Soviet Union, Australia, southern South America, the whole Mediterranean zone, the Middle East, parts of Africa) (1-3).

Hydatid disease mainly involves the liver and lung, but may secondarily affect other organs. Primary involvement of other organs is a known but rare clinical entity; thus, in such a case, diagnosis may be delayed, and it may lead to complications. In this report, we describe a case of hydatid disease in an unusual location.

CASE REPORT

A 62-year-old woman was admitted to our outpatient clinic with a palpable mass over her thoracic spine. She had been having pain for 5 months before the lesion appeared. She lived in an animal farm in a rural site 30 years previously. She had no prior history of trauma, fever, or weight loss. Her physical examination was unremarkable, except for the palpable, moderately mobile mass over the thoracic spine. Routine laboratory findings were within normal limits, except her anemia. Erythrocyte sedimenta-

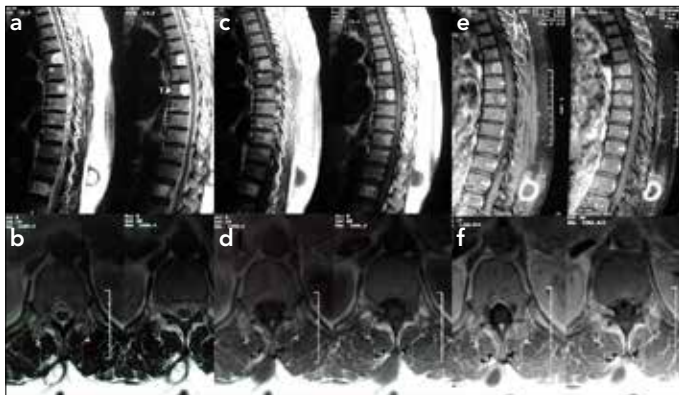


Figure 1. a-f. On T2-weighted MR images (a, b) a hyperintense cystic lesion with a hypointense rim is seen. On T1-weighted MR images (c, d), the whole lesion is hypointense. After IV-gadolinium injection (e, f), the cyst is hypointense with surrounding hyperintense parenchyma

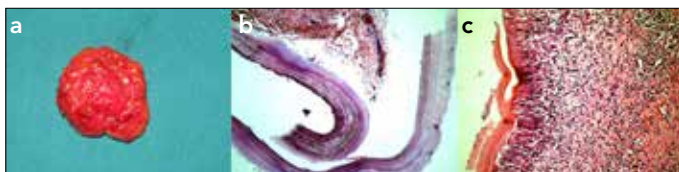

Figure 2. a-c. Total excision of the cyst with an intact cyst wall is achieved (a), Cuticular membrane and chronic inflammation with palisaded histiocytes, (H&E, x 100) (b), Microscopical appearance of the cyst wall shows an outer chitinous layer. (H&E, x 200) (c)

tion rate and C-reactive protein level were normal. Her neurological examination was nonspecific. On thoracic magnetic resonance (MR) imaging, the lesion was hypointense and hyperintense on T1- and T2-weighted images, respectively, with a hypointense rim on both scans (Figure 1a-d). After IV gadolinium application, the lesion was enhanced (Figure 1e, f). The patient was operated on, and the cystic mass was totally excised (Figure 2a) and measured 3×2.5×4 cm. Before closure, the cavity was scrubbed with povidone-iodine solution. Pathological diagnosis was a hydatid cyst (*E. granulosus*) (Figure 2b, c). The patient was referred to an infectious disease specialist. The indirect hemagglutination test was positive for *Echinococcus* antigen at 1/512 dilution. Imaging studies [central nervous system MR imaging, PA chest radiography, abdominal ultrasonography (USG)] were negative for other possible locations for the disease. She was given a 3-month trial of albendazole 400 mg twice daily and evaluated every 2 weeks with complete blood count (CBC) and liver function tests. After 3 months, her serological test became negative, and albendazole was stopped. There were neither local nor systemic recurrences.

DISCUSSION

Echinococcus granulosus is a cestode (1). Its intermediate hosts are wild and domestic ungulates, and its definitive hosts are canids (1, 3, 5). Humans are an accidental intermediate host (5). The hydatid cyst is a unilocular, fluid-filled cyst and is composed of two compartments: inner germinal layer and outer acellular acidophilic-staining laminated membrane (1, 5). With time, the germinal layer produces brood capsules, leading to the appearance of daughter cysts (1).

Humans are infected directly with parasite eggs released in definitive hosts' feces or indirectly by contamination via water, food, or arthropods. Eggs release embryos in the small intestine. Embryos penetrate the bowel wall and pass to the liver via blood (1, 3, 5). In our case, there were no other sites of infection other than subcutaneous tissue. This might have occurred by dissemination through the lymphatic system, bypassing the liver (3, 5). In the viscera, embryos develop into a cystic structure. In most human infections, a single cyst is detected, but in 20-40% of patients, multiple cysts or multiple organ involvement are detected (1, 5). In adults, the most commonly infected organ is the liver (>65%), and the second most commonly infected organ is the lung (25%) (1, 4). The cyst is less common in other organs such as the central nervous system, heart, bone (1-4%), spleen (<2%), pancreas (0.2-2%), peritoneal cavity (13%), kidney (3%), adrenal gland, ovary, breast, omentum, retroperitoneum, mediastinum, muscles, pelvic organs, and salivary glands (1-4). Subcutaneous involvement is usually reported to be caused by iatrogenic spillage of cyst contents to the subcutaneous tissue (2). Primary subcutaneous involvement is a rare entity in the literature (incidence: 0.2-2%) (3, 6). The most common location reported in the literature is the thigh (27%) (2, 3, 6-16). The main presenting complaint is a slowly growing mass just under the intact skin (6). In the English literature, to the best of our knowledge, this is the first case report of thoracic primary subcutaneous hydatid disease. There has been only one case of recurrence against all therapy methods applied (Table 1) (2-3, 6-37).

Table 1. Primary subcutaneous hydatid disease cases in the literature

Authors	Patient age (years)/sex	Cyst location	Presentation	Treatment	Follow-up time	Recurrence
Chevalier et al. (7)	40/M	Thigh	Slowly growing tender mass	Needle aspiration, surgery, post-operative albendazole treatment for 2 months	2 months	N/A
Voucharas et al. (8)	50/F	Thigh	Rubbery consistency, non-tender mass	Surgery	N/A	N/A
Ok and Sozuer (17)	12/F	Submandibular	Fluctuant, mobile, and painless mass	Surgery	4 years	No
Ozturk et al. (18)	20/M	Face	Slowly growing, painless, firm, and slightly mobile mass	Surgery	14 months	No
Baldi et al. (9)	54/F	Scapula	N/A	Surgery	5 years	No
Orhan et al. (19)	43/F	Thigh	Painful, erythematous mass	Surgery, post-operative albendazole treatment for 1 month	1 month	No
Losanoff et al. (20)	38/M	Axillary region	Painless, round, palpable mass	Surgery	N/A	N/A
Bedioui et al. (10)	70/F	Hypogastric area	N/A	Surgery	N/A	N/A
Parsak et al. (21)	29/F	Thigh	Painful, immobile mass	Surgery, post-operative albendazole treatment for 6 months	1 year	No
Safioleas et al. (11)	73/M	Gluteal	Slowly growing, painless mass	Surgery, post-operative albendazole treatment for 4 months	3 years	No
Dirican et al.(22)	64/M	Thigh	Fluctuant, mobile, and painless mas	Surgery, post-operative albendazole treatment for 3 months	3 years	No
	67/M	Palm	Swelling mass	Surgery, post-operative albendazole treatment for 3 months	3 years	No
Daoudi et al. (12)	21/F	Gluteal	Painless, swelling mass	Surgery	36 months	No
Săvulescu et al. (3)	46/F	Thigh	Painless, round, palpable mass	Surgery, post-operative albendazole treatment for 3 months	1 year	No
Ozkan and Sahin (2)	84/F	Thigh	Painless mass	Biopsy, died because of congestive heart failure before surgery and adjuvant albendazole therapy	N/A	N/A
Singal et al. (23)	26/F	Thigh	Swelling, non-tender mass	Surgery, post-operative albendazole treatment for 3 months	1 year	No
Battyany et al. (24)	63/M	Popliteal fossa	Painless, hyperemic mass	Needle aspiration, surgery, pre- and post-operative mebendazole treatment	5 years	3 times. Re-operated in each time. Mebendazol treatment for 3 months after 1 st recurrence.
Sallami et al. (25)	42/M	Lumbar	Slowly growing, painless mass	Surgery	6 years	No
Ousadden et al. (26)	70/F	Abdominal wall	Fluctuant, mobile, and painless mass	Surgery	2 years	No
Bansal et al. (13)	42/M	Face	Slowly growing mass	Surgery, 6 weeks albendazole (800mg/day)	22 months	No
Pathak et al. (27)	30/F	Thigh	Slowly growing, smooth, swelling mass	Pre-operative albendazole (10-15mg/kg/day) for 1 month, surgery, post-operative albendazole for 1 month	1 year	No

Table 1. Continued

Mushtaque et al. (28)	N/A	Gluteal	Palpable lump	Surgery, post-operative albendazole (10mg/kg/day) for 3 cycles (21 days each cycle)	N/A	N/A
	N/A	N/A	Palpable lump	Surgery, post-operative albendazole (10mg/kg/day) for 3 cycles (21 days each cycle)	N/A	N/A
Rais et al. (14)	58/F	Scalp	Palpable mass	Surgery	N/A	N/A
Gupta et al. (29)	38/M	Thigh	Swelling	Surgery, post-operative albendazole 400 mg	8 months	No
Abhishek et al. (30)	60/F	Abdomen	Painless swelling	Pre-operative albendazole, surgery, post-operative albendazole+ praziquantel for 3 months	6 months	No
Jarboui et al. (31)	53/F	Supraclavicular region	Slowly growing, hard, erythematous, painful mass	Surgery, post-operative albendazole (400mg/day) for 8 weeks	4 months	No
Ozdemir et al. (32)	29/F	Shoulder	Painful swelling	Surgery, post-operative albendazole 800mg/day for 28 day (repeated for 3 cycles with 14 days intervals)	N/A	N/A
Vecchio et al. (33)	68/M	Shoulder	Painless, slowly growing mass	Surgery, post-operative albendazole 800mg/day for 28 days	6 months	No
Burgazli et al. (34)	63/M	Abdomen	Palpable, slowly growing mass	Surgery, post-operative albendazole 10 mg/kg/day for 3 months	N/A	N/A
Ay et al. (15)	53/F	Temporomandibular region	Painful swelling	Surgery, post-operative albendazole 10 mg/kg	6 months	No
	37/F	Scapula	Swelling	Surgery, post-operative albendazole 10 mg/kg	6 months	No
Almadani et al. (35)	53/M	Thigh	Rounded, firm mass	Surgery	N/A	N/A
Okus et al. (16)	N/A	Back	N/A	Surgery	N/A	N/A
	N/A	Face	N/A	Surgery	N/A	N/A
Yucesoy et al. (36)	44/F	Thigh	Giant, soft mass	Percutaneous treatment	N/A	N/A
Haslak and Uysal (37)	37/F	Lumbar	Palpable mass	Surgery, post-operative albendazole 400 mg for 3 months	1 year	No
Present case	62/F	Thoracic	Painful, palpable mass	Surgery, post-operative albendazole treatment for 3 months	1 year	No

Abbreviations: M: Male, F: Female, N/A: Not available

The hydatid cyst enlarges progressively; thus, the clinical symptoms and signs may appear according to tolerability of the organ involved. In patients with the infected liver and lung, it presents at a later stage, while in patients with brain or eye involvement, it is usually detected at an early stage (1). Clinical manifestations differ according to the cyst size, location, and condition of the cyst itself (1, 3). Nevertheless, above all these, rupture of the cyst may cause allergic reactions independent of the involvement site (1). Hydatid disease has a mortality rate of 4% (4).

In endemic areas, differential diagnosis should include hydatid disease in the presence of cystic lesions. Other diseases included in differential diagnosis are abscesses, hematomas, mycoses, benign cysts, benign or malignant neoplasms, tuberculosis, and aneurysms (1-3). Radiological assessment combined with immunohistochemical techniques helps in making correct diagnosis

(1-4). MR imaging, computed tomography (CT) scan, USG, and sometimes plain radiography are valuable radiologic tools for assessment of cysts in all organs (1-5). Special radiologic properties include cyst wall calcification, daughter cyst, and detached germinal membrane (2, 4). MR imaging is superior to others for cutaneous imaging (2). A pathology-based classification with radiological correlation has been described by Lewall in 1998 (5). The classification is summarized in Table 2. The cyst in our case had a unilocular appearance without daughter cysts, representing a type I cyst.

ELISA and indirect hemagglutination are useful tests for serum screening (1, 3). In our case, after histopathologic diagnosis of the hydatid cyst, the indirect hemagglutination test was positive (at 1/512 dilution). It is important to remember that intact, unruptured cysts do not release proteins and do not cause immuno-

Table 2. Classification based on pathology, in correlation with radiology

Type	Imaging findings
I	Round or oval and unilocular in structure. Hypointense on T1- and hyperintense on T2-weighted MR imaging. A hypointense rim can be seen on T2-weighted scans. Density is close to water on CT.
II	Contains daughter cysts and/or matrix inside. Cyst wall calcification may be present. Daughter cysts are hypodense on CT, hypo/ isointense on T1 and hyperintense on T2 MR scans. Floating membranes called as serpentine structures, have low-intensity appearance on both T1- and T2-weighted MR images.
III	Degenerated cyst with calcification foci. Calcifications appear as round areas with hyperdense (CT) and hypointense (MR) imaging properties.

logical reactions; hence, serology screening can be falsely negative in this condition (1).

Surgery with total resection, if applicable, is the main therapy. During resection, the wall should be kept intact. If not, dissemination of the disease and anaphylaxis may occur. Endocystectomy, pericystectomy, marsupialization, capitonage, simple drainage of the cyst, and resection of the infected organ are surgical methods used in daily practice (1, 2, 5). Pregnancy, multiple cysts, unsuitable medical condition, and patient's avoidance are main contraindications for surgery. In such circumstances, puncture, aspiration, injection, reaspiration (PAIR) and medical treatment are methods of choice (1, 5). After 1980s, benzimidazole compounds were introduced. Their efficiency has been confirmed by many clinical trials (1). A complete cure can be achieved in one-third of patients. In considerable percent of patients (30-50%), regression of cyst size is achieved (1). Albendazole (10-15 mg/kg/day) is a better drug than mebendazole (40-50 mg/kg/day) because of its pharmacokinetic properties. Minimal treatment period is 3 months. In our case, after diagnosis, the patient used albendazole for 3 months. Serological test became negative, and treatment was stopped with ongoing outpatient follow-ups.

CONCLUSION

Diagnosis of hydatid disease in organs other than the liver or lung sometimes is not straightforward and causes delay in treatment. In endemic areas, hydatid disease should be taken into consideration for differential diagnosis when a cystic lesion is identified in any organ of the body. In cases of primary subcutaneous hydatid disease, en bloc resection is the treatment of choice. After resection, treatment with benzimidazole regimens is mandatory to prevent recurrences.

Informed Consent: Written informed consent was obtained from the patient who participated in this case.

Peer-review: Externally peer-reviewed.

Author contributions: Concept - Y.B., M.Ş.E., D.K.; Design - Y.B., M.Ş.E., D.K.; Supervision - Y.B., D.K.; Resource - S.U.B., D.K.; Materials - D.K., S.U.B.; Data Collection&/or Processing - Y.B., M.Ş.E., A.S.; Analysis&/or Interpretation - Y.B., M.Ş.E., A.S.; Literature Search - Y.B., M.Ş.E., A.S.; Writing - M.Ş.E., Y.B., A.A.; Critical Reviews - D.K., Y.B.

Acknowledgements: We thank Gülcan Davulcu and Arınç Arpınar for their technical support in preparing the images.

Conflict of Interest: The authors declare that they have no conflict of interest.

Financial Disclosure: The authors declared that this study has received no financial support.

Hasta Onamı: Yazılı hasta onamı bu çalışmaya katılan hastalardan alınmıştır.

Hakem değerlendirmesi: Dış bağımsız.

Yazar Katkıları: Fikir - Y.B., M.Ş.E., D.K.; Tasarım - Y.B., M.Ş.E., D.K.; Denetleme - Y.B., D.K.; Kaynaklar - S.U.B., D.K.; Malzemeler - D.K., S.U.B.; Veri toplanması ve/veya işlemesi - Y.B., M.Ş.E., A.S.; Analiz ve/veya yorum - Y.B., M.Ş.E., A.S.; Literatür taraması - Y.B., M.Ş.E., A.S.; Yazıyı yazan - M.Ş.E., Y.B., A.A.; Eleştirel inceleme - D.K., Y.B.

Teşekkür: Teknik destek ve görsellerin hazırlanmasına katkıda bulunan Gülcan Davulcu'ya ve Arınç Arpınar'a teşekkür ederiz.

Çıkar Çatışması: Yazarlar çıkar çatışması bildirmemişlerdir.

Finansal Destek: Yazarlar bu çalışma için finansal destek almadıklarını beyan etmişlerdir.

REFERENCES

- Moro P, Schantz PM. Echinococcosis: a review. *Int J Infect Dis* 2009; 13: 125-33. [\[CrossRef\]](#)
- Ozkan HS, Sahin B. Primary hydatid disease of subcutaneous tissue in the leg. *Clin Exp Dermatol* 2010; 35: 915-6. [\[CrossRef\]](#)
- Savulescu F, Iordache II, Hristea R, Dumitru C, Sandru AM, Balasa G, et al. Primary hydatid cyst with an unusual location--a case report. *Chirurgia (Bucur)* 2010; 105: 419-22.
- Yüksel M, Demirpolat G, Sever A, Bakaris S, Bulbuloglu E, Elmas N. Hydatid disease involving some rare locations in the body: a pictorial essay. *Korean J Radiol* 2007; 8: 531-40. [\[CrossRef\]](#)
- Lewall, DB. Hydatid disease: biology, pathology, imaging and classification. *Clin Radiol* 1998; 53: 863-74. [\[CrossRef\]](#)
- Kayaalp C, Dirican A, Aydin C. Primary subcutaneous hydatid cysts: a review of 22 cases. *Int J Surg* 2011; 9: 117-21. [\[CrossRef\]](#)
- Chevalier X, Rhamouni A, Bretagne S, Martigny J, Larget-Piet B. Hydatid cyst of the subcutaneous tissue without other involvement: MR imaging features. *AJR Am J Roentgenol* 1994; 163: 645-6. [\[CrossRef\]](#)
- Voucharas C, Papaioannidis D, Papamichael K. Subcutaneous mass of the right thigh. *Postgrad Med J* 1998; 74: 287-8. [\[CrossRef\]](#)
- Baldi A, Rossiello L, Rossiello R, Baldi F. Echinococcal cysts with primary cutaneous localization. *Br J Dermatol* 2002; 147: 807. [\[CrossRef\]](#)
- Bedioui H, Makni A, Noura K, Mekni A, Daghfous A, Ayadi S et al. Subcutaneous hydatid cyst. Case report of an exceptional location. *Med Trop (Mars)* 2007; 67: 181-2.
- Safioleas M, Nikiteas N, Stamatakos M, Safioleas C, Manti CH, Revenas C, et al. Echinococcal cyst of the subcutaneous tissue: a rare case report. *Parasitol Int* 2008; 57: 236-8. [\[CrossRef\]](#)

12. Daoudi A, Loudiyi WD, Elibrahimi A, Elmrini A, Chakour K, Boutayeb F. Solitary subcutaneous hydatid cyst of gluteal area: an unusual localisation. A case report. *Ann Chir Plast Esthet* 2008; 53: 448-51. [\[CrossRef\]](#)
13. Bansal C, Lal N, Jain RC, Srivastava AN, Fatima U. Primary hydatid cyst in the soft tissue of the face: An exceptional occurrence. *Indian J Dermatol* 2011; 56: 768-7. [\[CrossRef\]](#)
14. Rais H, Jghaimi F, Bassi L, Ziad T, Cherif Idrissi El Ganouni N, Belaabidia B. Hydatid cyst of the scalp. *Rev Stomatol Chir Maxillofac* 2012; 113: 472-4. [\[CrossRef\]](#)
15. Ay S, Okus A, Demirgul R, Eryilmaz MA, Atay A. Primary subcutaneous cyst hydatid: presentation of two cases. *Turkiye Parazitoloj Derg* 2013; 37: 219-21. [\[CrossRef\]](#)
16. Okus A, Sevinc B, Ay S, Karahan O, Eryilmaz MA, Er C. Relation between serology and grow-up time in atypically localized hydatid cysts. *Turkiye Parazitoloj Derg* 2013; 37: 257-61. [\[CrossRef\]](#)
17. Ok E, Sozuer EM. Solitary subcutaneous hydatid cyst: a case report. *Am J Trop Med Hyg* 2000; 62: 583-4.
18. Ozturk S, Devec M, Yildirim S. Hydatid cyst in the soft tissue of the face without any primary. *Ann Plast Surg* 2001; 46: 170-3. [\[CrossRef\]](#)
19. Orhan Z, Kara H, Tuzuner T, Sencan I, Alper M. Primary subcutaneous cyst hydatid disease in proximal thigh: an unusual localisation: a case report. *BMC Musculoskelet Disord* 2003; 4: 25. [\[CrossRef\]](#)
20. Losanoff JE, Richman BW, Jones JW. Primary hydatid cyst of the axilla. *ANZ J Surg* 2004; 74: 393-4. [\[CrossRef\]](#)
21. Parsak CK, Eray IC, Sakman G, Eray SI, Gumurdurlu D, Akcam T. Hydatid disease involvement of primary subcutaneous tissue in the posterior proximal thigh--an unusual localization. *Int J Dermatol* 2008; 47: 417-8. [\[CrossRef\]](#)
22. Dirican A, Unal B, Kayaalp C, Kirimlioglu V. Subcutaneous hydatid cysts occurring in the palm and the thigh: two case reports. *J Med Case Rep* 2008; 2: 273. [\[CrossRef\]](#)
23. Singal R, Dalal U, Dalal AK, Singh P, Gupta R. Subcutaneous hydatid cyst of the thigh. *South Med J* 2010; 103: 965-6. [\[CrossRef\]](#)
24. Battyany I, Andrea L, Nagy KK. Subcutaneous hydatid cyst in the popliteal fossa at the site of a previous wasp sting. *Diagn Interv Radiol* 2011; 17: 163-5.
25. Sallami S, Ayari K, Oueslati B, Miladi M. Isolated subcutaneous hydatid cyst. *Tunis Med* 2011; 89: 314-5.
26. Ousadden A, Elboughaddouti H, Ibnmajdoub KH, Mazaz K, Aittaleb K. A solitary primary subcutaneous hydatid cyst in the abdominal wall of a 70-year-old woman: a case report. *J Med Case Rep* 2011; 5: 270. [\[CrossRef\]](#)
27. Pathak TK, Roy S, Das S, Achar A, Biswas AK. Solitary hydatid cyst in thigh without any detectable primary site. *J Pak Med Assoc* 2011; 61: 1244-5.
28. Mushtaque M, Mir MF, Malik AA, Arif SA, Khanday SA, Dar RA. Atypical localizations of hydatid disease: Experience from a single institute. *Niger J Surg* 2012; 18: 2-7.
29. Gupta A, Singal RP, Gupta S, Singal R. Hydatid cyst of thigh diagnosed on ultrasonography-a rare case report. *J Med Life* 2012; 5: 196-7.
30. Abhishek V, Patil VS, Mohan U, Shivswamy BS. Abdominal wall hydatid cyst: case report and review of the literature. *Case Rep Surg* 2012; 2012: 583294.
31. Jarboui S, Hlel A, Daghfous A, Bakkey MA, Sboui I. Unusual location of primary hydatid cyst: soft tissue mass in the supraclavicular region of the neck. *Case Rep Med* 2012; 2012: 484638.
32. Ozdemir G, Zehir S, Ozdemir BA, Sipahioğlu S, Severge U. Hydatid cyst involvement of shoulder and deltoid muscle: a case report. *Eklem Hastalik Cerrahisi* 2012; 23: 173-6.
33. Vecchio R, Marchese S, Ferla F, Spataro L, Intagliata E. Solitary subcutaneous hydatid cyst: review of the literature and report of a new case in the deltoid region. 2013; 62: 487-93.
34. Burgazli KM, Ozdemir CS, Beken Ozdemir E, Mericliler M, Polat ZP. Unusual localization of a primary hydatid cyst: a subcutaneous mass in the paraumbilical region. *Eur Rev Med Pharmacol Scie* 2013; 17: 1766-8.
35. Almadani N, Almutairi B, Alassiri AH. Primary subcutaneous hydatid cyst with palisading granulomatous reaction. *Case Rep Pathol* 2013; 2013: 126541.
36. Yucesoy C, Ozturk E, Hekimoglu B. Radiologic findings and percutaneous treatment of a rare giant soft tissue hydatid cyst. *JBR-BTR* 2013; 96: 286-9.
37. Haslak A, Uysal E. Left lumbar subcutaneous hydatid cyst disease: a case report. *Turkiye Parazitoloj Derg* 2014; 38: 55-7. [\[CrossRef\]](#)