



The comparative effects of local anaesthetics on wound healing in rats: Bupivacaine vs Levobupivacaine

Yunus Oktay Atalay^{a*}, Tumay Umuroglu^b, Caglayan Yagmur^c, Fevzi Yilmaz Gogus^d, Suheyly Bozkurt^e

^a Department of Radiology, Outpatient Anesthesia Service, Ondokuz Mayıs University, Samsun, Turkey

^b Department of Anesthesiology and Reanimation, Marmara University, Istanbul, Turkey

^c Department of Plastic and Reconstructive Surgery, Ondokuz Mayıs University, Samsun, Turkey

^d Department of Anesthesiology, Academic Hospital, Istanbul, Turkey

^e Department of Pathology, Marmara University, Istanbul, Turkey

ARTICLE INFO

ABSTRACT

Article History

Received 08 / 02 / 2016

Accepted 03 / 04 / 2016

* Correspondence to:

Yunus Oktay Atalay
Department of Radiology,
Outpatient Anesthesia Service,
Faculty of Medicine,
Ondokuz Mayıs University,
Atakum, Samsun, Turkey
e-mail: dryunusatalay@gmail.com

The aim of this study is to investigate the effects of local anaesthetic agents (bupivacaine and levobupivacaine) on wound healing in rats. Wistar albino rats were randomly assigned to three groups (n=10 per group); the control group, the bupivacaine group, and the levobupivacaine group. An incision measuring 5 cm in length was made over the dorsum in all groups. The incisions were infiltrated with 3 ml of normal saline in the control group, 3 ml of 0.25% bupivacaine in the bupivacaine group, and 3 ml of 0.25% levobupivacaine in the levobupivacaine group. Histopathological examinations and tensile strength measurements were performed on tissue samples taken from the incision line 14 days after infiltration. Epidermal and dermal regeneration scores were significantly lower in the levobupivacaine group compared with the bupivacaine and control groups (p<0.05). Granulation tissue thickness, angiogenesis, and tensile strength measurements were not significantly different between groups. Even though incomplete epidermal and dermal regeneration scores were attained using levobupivacaine, both bupivacaine and levobupivacaine had no negative effects on the overall clinical wound-healing process.

Keywords:

Bupivacaine
Infiltration anaesthesia
Levobupivacaine
Local anaesthetics
Wound healing

© 2016 OMU

1. Introduction

Pain is an activator of the stress response and can result in widespread inflammation, increased catabolism, and poor wound healing (McGuire et al., 2006). Effective postoperative pain management increases patient comfort, enhances recovery, and decreases both

cardiopulmonary complications and hospitalization lengths. Among the multimodal postoperative analgesia approaches, incisional infiltration of local anaesthetic (LA) agents is a simple, safe, and inexpensive method (Scott, 2010; Whiteman et al., 2011). LA agents can also be applied by continuous wound perfusion via a

catheter or sustained-release LA preparations to the wound (Brower and Johnson, 2003). The effects of LA agents on wound healing is an important issue to evaluate for a complication-free wound-healing process that can affect postoperative morbidity (Dere et al., 2009). LA agents used in infiltration anaesthesia have been reported to have detrimental effects on wound healing, as shown in some animal and in vitro studies (Chvapil et al., 1979; Waite et al., 2010). The most common LA agents investigated in this field have been lidocaine and bupivacaine (Waite et al., 2010).

Bupivacaine is one of the most used LAs in clinical practices. Based on observations of cardiotoxicity with racemic bupivacaine, the S (-) enantiomer form (levobupivacaine) of bupivacaine has been developed and become popular in clinical use (Foster and Markham, 2000). Nevertheless, few studies have been conducted on the wound-healing effects of levobupivacaine when used for infiltration anaesthesia and there is no known study comparing the effects of bupivacaine and its S (-) enantiomer levobupivacaine on the wound-healing process (Dere et al., 2009; Zeren et al., 2013). Therefore, we performed an experimental study to compare the histopathological effects and the tensile strength values of bupivacaine and levobupivacaine on wound healing.

2. Experimental procedure

The experimental protocol was approved by the Institutional Animal Care and Use Committee of Marmara University, Istanbul, Turkey, and was conducted according to the tenets of the National Institutes of Health Guide for the Care and Use of Laboratory Animals.

We conducted this study with 30 Wistar albino rats (8-10 weeks old) weighing 250-300 g in the Experimental Animals and Application Research Center of Marmara University, Istanbul, Turkey. The animals were fed ad libitum, housed in pairs in steel cages in a temperature-controlled environment (22±1 °C), and exposed to a 12h/12h light/dark cycle. All rats were randomly allocated into three study groups: the control group (group C, n=10), the bupivacaine group (group B, n=10), and the levobupivacaine group (group L, n=10).

Anaesthesia was induced with 75 mg/kg doses of intraperitoneal ketamine hydrochloride (Ketalar®; Eczacibasi, Istanbul, Turkey). After the loss of the corneal reflex and extremity drawing response, the hair on the back of the rat was removed with an electric razor. The incision area was cleaned with a povidone-iodine solution and covered with a sterile drape. The area was wiped dry with sterile gauzes after two minutes. An incision of skin and subcutaneous tissue 5 cm in length was made using a scalpel under sterile conditions.

The incisions were infiltrated with 3 ml of normal saline in Group C, 2.5 mg/ml bupivacaine (3 ml) in group B, and 2.5 mg/ml levobupivacaine (3 ml) in group L. Tissues were then closed with 3/0 silk sutures. No antibiotics were administered throughout the procedure. Rats were fed regular rat chow and tap water until they were euthanized and decapitated on day 14. Wound healing was assessed by two methods; histopathological examinations and measurements of the breaking strength using a horizontal tensiometer.

Histopathological examination

A band of 12×5 cm tissue samples that included cutaneous and subcutaneous tissue were taken from the incision line about 2 cm of this sample was kept for histopathological examination. Tissue samples were fixed with 10% formalin for 24 h. The samples were then embedded in a paraffin block, and 6 µm cross sections were cut from the tissue samples. These cross sections were stained with haematoxylin and eosin. One pathologist who was blinded to the experimental groups performed histologic assessments with a light microscope. Samples were evaluated under a magnification of 10× and 40× objectives and then photographed. The scoring system defined by Gercek et al. (2007) was used for histopathologic assessment (epidermal and dermal regeneration, granulation tissue thickness, and angiogenesis formation) as shown in Table 1.

Table 1. The scoring system for histopathological assessment of wound tissue samples

Scores	Epidermal and dermal regeneration	Granulation tissue thickness	Angiogenesis
1	Little organisation	Thin	1-2 per area High degree edema Hemorrhage Rare congestion
2	Moderate organisation	Moderate	3-6 per area Moderate edema Hemorrhage Rare congestion
3	Complete epidermal dermal maturation	Thick	7-10 per area Moderate edema Congestion
4		Very thick	>10 per area Mild edema

Breaking strength measurement

The remaining tissue was stored in 0.9% saline prior to the measurement of the tensile strength. This measurement was performed on the same day as the histopathological examinations. Wound length was measured using a ruler. Edges of the tissue were attached to either side of the tensiometer. A 10-N uniaxial horizontal tensiometer (Alfred J. Amsler & Co., Schaffhausen, Switzerland) was used. Tissues were stretched while applying a force of 1 N/min

(Fig. 1). Application of the force was continued until a tear developed anywhere along the incision. A graph reflecting the force applied to the tissue was obtained by a pencil and paper attached to the tensiometer. When a tear occurred, a sudden decrease in the line was detected, and the value corresponding to this decrease on the graph was recorded. This value was the power of the tear force expressed in kilograms. The breaking strength force per unit of tissue was calculated by dividing the measured force by the wound length.



Fig. 1. Measurement of a tensile strength of the wound tissue via a tensiometer.

Statistical analysis

The statistical analysis was performed with the Kruskal-Wallis test for epidermal regeneration, granulation tissue thickness, and angiogenesis. We used the Statistical Package for Social Sciences version 15.0 (SPSS Inc. Chicago, IL, USA) for Windows. The statistical significance of the breaking strength measurements was determined by a one-way analysis of variance (ANOVA) and then by Tukey's post-hoc test. Data were expressed as mean \pm standard deviation. The differences between groups were considered statistically significant at a p value of <0.05 .

3. Results

With regard to epidermal and dermal regenerations, no statistically significant differences were determined in groups C and B. However, the number of rats with a score of 3 (complete epidermal-dermal maturation) in group L was significantly lower than that in groups C and B (Table 1 and Fig. 2) ($p < 0.05$). No significant differences in granulation tissue thickness, angiogenesis formation, and tensile strength values were observed among the groups (Tables 2, 3 and Fig. 2).

Table 2. Histopathological scores of all groups

	Group C (n=10)	Group B (n=10)	Group L (n=10)
Epidermal and dermal regeneration scores	3 (2-3)	3 (2-3)	2 (1-3)*
Granulation tissue thickness scores	2 (1-3)	2.3 (2-3)	3 (2-3)
Angiogenesis formation scores	4 (4-4)	4 (2-4)	4 (4-4)

The scores are expressed as median(max-min)
* $p < 0.01$, compared to score groups C and B

In the histopathological evaluation, no change was observed in one of the rats in group L. Thus, the statistical analyses of epidermal regeneration, granulation tissue thickness, and angiogenesis were performed in nine rats in this group. However, the statistical analysis of the tensile strength data was carried out in all rats in this group.

Table 3. Tensile strength values of all groups

	Group C (n=10)	Group B (n=10)	Group L (n=10)
Tensile strength value (Newton / cm ²)	0.66 \pm 0.21	0.54 \pm 0.22	0.64 \pm 0.20

Values are expressed as mean \pm SD

4. Discussion

Results of the present study indicate that although epidermal and dermal regenerations were poor in the levobupivacaine group, the LAs studied did not affect

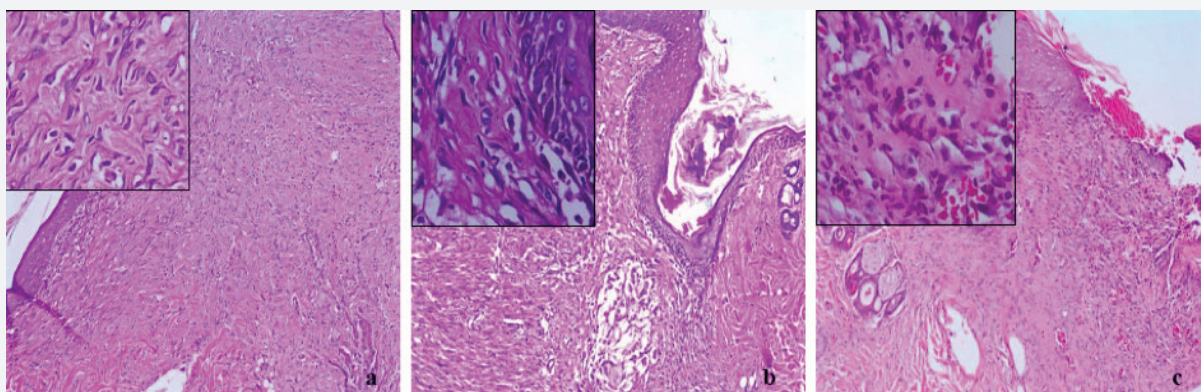


Fig. 2a. Regeneration of the epidermis and dermis, increase in angiogenesis in group C **b.** Regeneration of the epidermis and dermis in group B **c.** Diffuse ulceration in the epidermis, an increase in the fibroblast activity, and vascular structure reaching the superficial layer perpendicularly in group L (H&E, original magnification $\times 100$, inset $\times 400$).

the tensile strength of the wound.

Current literature findings on the LA effects on wound healing appear to be contradictory. There are some *in vivo* and *in vitro* studies with LA agents (lidocaine, bupivacaine, procaine, benzocaine, tetracaine, ropivacaine, and levobupivacaine) that assessed their effects on wound healing. However, these studies reported neutral, negative, or positive effects (Brower and Johnson, 2003; Zeren et al., 2013). The majority of these studies suggest that all commercially available LA agents inhibit the inflammatory and granulation/proliferation stages (i.e., the first and second stages of healing) (Brower and Johnson, 2003).

We assessed the effects of bupivacaine and levobupivacaine on wound healing using two different methods. The first method was a histopathological evaluation. In a study examining the infiltration of bupivacaine and lidocaine in the ventral abdominal midline (linea alba) of rabbits, the authors evaluated the histopathologic appearance and breaking strength of the wounds and reported no significant delaying effect on wound repair (Vasseur et al., 1984). These findings are consistent with the findings from our study. In another study with lidocaine and bupivacaine in mice; the authors reported an influence on local inflammatory and proteolytic factors but no effect on wound-healing rates (Waite et al., 2010). In our study, the bupivacaine group showed similar epidermal and dermal regenerations as the control group, however, the regeneration scores in the levobupivacaine group were poor. This finding supports the fact that LA agents cause some detrimental changes in the second stage of the wound-healing process (Zeren et al., 2013). The differences between epidermal and dermal regeneration scores of bupivacaine and levobupivacaine can be explained by the differences in their vasoactivities or their effect on neurogenic inflammation.

Drugs that cause vasoconstriction have a limited systemic uptake and stay for a longer duration at the affected site (Newton et al., 2000). In a study investigating the vasoactivity of bupivacaine and levobupivacaine in human skin, the authors reported a decreased dose-dependent vasodilatation with the levobupivacaine group (Newton et al., 2005). The vasoconstrictive potency of levobupivacaine has been studied in the sciatica nerve, the aorta and basilar artery of rats, and also in humans during tonsillectomy and nasal surgery. All of these studies reported a vasoconstrictive activity with levobupivacaine concentrations of 0.25% or lower (Bouaziz et al., 2005; Demiraran et al., 2008; Ergil et al., 2012; Shim et al., 2012; Ergil et al., 2015). Successful surgical wound healing requires adequate tissue perfusion to transport oxygen, neutrophils, and nutrients needed for the wound-healing process. Among the factors affecting tissue perfusion, vasoconstriction is an important

element (Buggy, 2000). In our study, we considered that the relatively high vasoconstrictive activity of levobupivacaine at the beginning of the wound-healing process might have resulted in low tissue perfusion and delayed epidermal and dermal regeneration.

Another perspective regarding the effect of local anaesthetic solutions on wound healing may be related to "neurogenic inflammation" (Engin, 1998; Smith and Liu, 2002). Although its role is underestimated, the nervous system is involved in wound healing. The sensory nerve endings in the skin also have secretory functions like nociceptors. Anterograde action potentials in neighbouring branches (axon reflex) by retrograde invasion of primary afferent neuron arborisations may also be formed in the level of the dorsal root ganglia (Yaprak, 2008). Through this type of reflex, the nociceptors of the skin may secrete major mediators of neurogenic inflammation (neuropeptides) into the wound environment (O'Sullivan et al., 1998; Schmelz and Petersen, 2001). It may sound reasonable that local anesthetic solutions applied to the wound environment may diminish inflammatory processes by inhibiting action potentials of free nerve endings, thereby reducing neuropeptide release and eventual neurogenic inflammation.

The other microscopic examination performed in our study was the assessment of granulation tissue thickness and angiogenesis, which are necessary to sustain the newly formed granulation tissue (Singer et al., 1999). Granulation tissue thickness and angiogenesis scores were similar between groups. These similar scores with levobupivacaine combined with a delayed epidermal and dermal regeneration may be due to granulation and angiogenesis beginning later in the epithelisation phase.

Other studies examining the effects of levobupivacaine on wound healing have also evaluated the fibrotic indices of the tissues (Dere et al., 2009; Zeren et al., 2013). However, their findings appear to be contradictory. Dere et al. (2009) claimed that levobupivacaine had a concentration-dependent positive effect on both fibrotic indices and tension strength on the eighth day. Alternatively, Zeren et al. (2013) reported a negative relationship between the fibrotic index and wound tension strength also on the same day; they further proposed that this was due to the negative effect of levobupivacaine on collagen structure. However an increase in the fibrotic index and collagen amounts do not always indicate that a wound will have good strength. Therefore, the evaluation of wound strength through the measurement of the fibrotic index has limitations in clinical practice (Zeren et al., 2013). The return of tensile strength is a clinical reflection of healing, thus, the measurement of breaking strength is more effective in the assessment of wound healing. We did not examine the fibroproliferative changes,

but we did measure the wound tension strength. In our study, the wound tension strengths of all groups were similar, which means tensile strength was not negatively affected by bupivacaine or levobupivacaine. According to one study, when the concentration of levobupivacaine increased, the breaking strength of the wound also increased (Dere et al., 2009). In another study 5, mg/ml bupivacaine had no detrimental effect on the breaking strength of the wound (Vasseur et al., 1984). Levobupivacaine, at concentrations as low as 1.25 mg/ml, has been shown to increase the breaking strength (Dere et al., 2009); therefore, we were not surprised that the breaking strength was not negatively affected by the concentration we used. Relevant studies have generally taken these measurements during the second week of wound healing when only 20% of the final strength had been reached (Brower and Johnson, 2003). We performed histopathological examinations and tensile strength measurements at day 14 following the incision because this was an average time that reflected all changes in wound healing. We aimed to examine the histopathological scores as well as tensile strength of the wound at the same time.

A major limitation of this study is the shortness of the evaluation period, which is also a common

limitation observed in other studies. The majority of these other studies have assessed the effects of LAs after one or three weeks (Brower and Johnson, 2003). However, evaluating the overall wound healing process before the end of 6-12 months (the remodeling phase of wound healing) may not be logical. Brower and Johnson (2003) claimed that even though the early stages of wound healing are affected by LAs, the third stage and the overall wound healing might not be affected. Another limitation is that, in clinical practice, examining the effects of LAs on human wound healing is not practical because measuring wound strength with non-destructive methods is impossible. Furthermore, conducting histopathological evaluations on human tissues to evaluate wound-healing effects is not ethical. Therefore, animal research is vital in this area of research.

In conclusion, although incomplete epidermal and dermal regenerations were noticeable with levobupivacaine. The use of bupivacaine and levobupivacaine had no deteriorating effects on the overall clinical wound-healing process. As studying the wound-healing process requires the examination of all stages, further studies involving these stages are required.

REFERENCES

- Bouaziz, H., Iohom, G., Estebe, J.-P., Campana, W., Myers, R., 2005. Effects of levobupivacaine and ropivacaine on rat sciatic nerve blood flow. *Br. J. Anaesth.* 95, 696-700. doi:10.1093/bja/aei242.
- Brower, M. C., Johnson, M. E., 2003. Adverse effects of local anesthetic infiltration on wound healing. *Reg. Anesth. Pain Med.* 28, 233-240.
- Buggy, D., 2000. Can anaesthetic management influence surgical-wound healing? *The Lancet.* 356, 355-357. doi: 10.1016/S0140-6736(00)02523-X.
- Chvapil, M., Hameroff, S. R., O'Dea, K., Peacock, E. E., 1979. Local anesthetics and wound healing. *J. Surg. Res.* 27, 367-371. doi: 10.1016/0022-4804(79)90155-0.
- Demiraran, Y., Ozturk, O., Guclu, E., Iskender, A., Ergin, M. H. Tokmak, A., 2008. Vasoconstriction and analgesic efficacy of locally infiltrated levobupivacaine for nasal surgery. *Anesth. Analg.* 106, 1008-1011. doi:10.1213/ane.0b013e31816174c3.
- Dere, K., Sen, H., Teksoz, E., Ozkan, S., Dagli, G., Sucullu, I., Filiz, A. I., Ipcioglu, O. M., Kucukodaci, Z., 2009. The comparison of the effects of different doses of levobupivacaine infiltration on wound healing. *J. Invest. Surg.* 22, 112-116. doi: 10.1080/08941930802713019.
- Engin, C., 1998. Effects of calcitonin gene-related peptide on wound contraction in denervated and normal rat skin: A preliminary report. *Plast. Reconstr. Surg.* 101, 1887-1890.
- Ergil, J., Akkaya, T., Gozaydin, O., Gunsoy, B., Alicura, S., Aladag, E., Gumus, H. Akin, I., 2012. Vasoconstrictive and analgesic efficacy of locally infiltrated levobupivacaine in tonsillectomy patients. *Int. J. Pediatr. Otorhinolaryngol.* 76, 1429-1433. doi: 10.1016/j.ijporl.2012.06.016.
- Ergil, J., Kertmen, H., Sayin, M., Güner, B., Yılmaz, E. R., Özkan, D., Arıkök, A. T., Kanat, M. A., Şekerci, Z., 2015. Experimental research vasoconstrictive effects of levobupivacaine on the basilar artery in the rabbit. *Arch. Med. Sci.* 11, 654-659. doi: 10.5114/aoms.2015.52372.
- Foster, R. H., Markham, A., 2000. Levobupivacaine: A review of its pharmacology and use as a local anaesthetic. *Drugs.* 59, 551-579. doi: 10.2165/00003495-200059030-00013.
- Gercek, A., Yildirim, O., Konya, D., Bozkurt, S., Ozgen, S., Kilic, T., Sav, A., Pamir, N., 2007. Effects of parenteral fish-oil emulsion (Omegaven) on cutaneous wound healing in rats treated with dexamethasone. *J. Parenter. Enteral. Nutr.* 31, 161-166. doi: 10.1177/0148607107031003161.
- McGuire, L., Heffner, K., Glaser, R., Needleman, B., Malarkey, W., Dickinson, S., Lemeshow, S., Cook, C., Muscarella, P., Melvin, W. S., 2006. Pain and wound healing in surgical patients. *Ann. Behav. Med.* 31, 165-172. doi: 10.1207/s15324796abm3102_8.
- Newton, D. J., Burke, D., Khan, F., McLeod, G. A., Belch, J. J., McKenzie, M., Bannister, J., 2000. Skin blood flow changes in response to intradermal injection of bupivacaine and levobupivacaine, assessed by laser Doppler imaging. *Reg. Anesth. Pain Med.* 25, 626-631.

- Newton, D., McLeod, G., Khan, F., Belch, J., 2005. Vasoactive characteristics of bupivacaine and levobupivacaine with and without adjuvant epinephrine in peripheral human skin. *Br. J. Anaesth.* 94, 662-667. doi: 10.1093/bja/aei095.
- O'Sullivan, R. L., Lipper, G., Lerner, E. A., 1998. The neuro-immuno-cutaneous-endocrine network: Relationship of mind and skin. *Arch. Dermatol.* 134, 1431-1435. doi: 10.1001/archderm.134.11.1431.
- Schmelz, M., Petersen, L. J., 2001. Neurogenic inflammation in human and rodent skin. *News Physiol. Sci.* 16, 33-37.
- Scott, N., 2010. Wound infiltration for surgery. *Anaesthesia.* 65, 67-75. doi: 10.1111/j.1365-2044.2010.06241.x.
- Shim, H.S., Ok, S.H., Lee, S. H., Kwon, S.C., Sohn, J.T., 2012. Protein kinases participate in the contraction in response to levobupivacaine in the rat aorta. *Eur. J. Pharmacol.* 677, 131-137. doi: 10.1016/j.ejphar.2011.12.023.
- Singer, A. J., Epstein, F. H., Clark, R. A., 1999. Cutaneous wound healing. *N. Engl. J. Med.* 341, 738-746.
- Smith, P. G. Liu, M., 2002. Impaired cutaneous wound healing after sensory denervation in developing rats: Effects on cell proliferation and apoptosis. *Cell Tissue Res.* 307, 281-291. doi: 10.1007/s00441-001-0477-8.
- Vasseur, P., Paul, H., Dybdal, N., Crumley, L., 1984. Effects of local anesthetics on healing of abdominal wounds in rabbits. *Am. J. Vet. Res.* 45, 2385-2388.
- Waite, A., Gilliver, S., Masterson, G., Hardman, M., Ashcroft, G., 2010. Clinically relevant doses of lidocaine and bupivacaine do not impair cutaneous wound healing in mice. *Br. J. Anaesth.* 104, 768-773. doi: 10.1093/bja/aeq093.
- Whiteman, A., Bajaj, S., Hasan, M., 2011. Novel techniques of local anaesthetic infiltration. *Contin Educ Anaesth Crit Care* 11, 167-171. doi: 10.1093/bjaceaccp/mkr026.
- Yaprak, M., 2008. The axon reflex. *Neuroanatomy.* 7, 17.
- Zeren, S., Kesici, S., Kesici, U., Isbilir, S., Turkmen, U. A., Ulusoy, H., Karpuz, V., Ozcan, O., Polat, E., Ipcioglu, O. M., 2013. Effects of levobupivacaine on wound healing. *Anesth. Analg.* 116, 495-499. doi: 10.1213/ANE.0b013e318273f48e.