

KEYHOLE ANTEROLATERAL THIGH FLAP: A SPECIAL WAY OF PARTITION FOR RECONSTRUCTION AROUND A PROTRUDING STRUCTURE OR CAVITY/TUNNEL

PORNTHPEP SIRIMAHACHAIYAKUL, M.D., F.R.C.S. (T),^{1,2} GEORGIOS ORFANIOTIS, M.B., Ch.B., M.R.C.S. (ENG),¹ KANELLOS GESAKIS, M.D.,¹ KIDAKORN KIRANANTAWAT, M.D., F.R.C.S. (T),^{1,3} PEDRO CIUDAD, M.D.,¹ FABIO NICOLI, M.D.,¹ MICHELE MARUCCIA, M.D.,^{1,4} BULENT SACAĞ, M.D.,¹ and HUNG-CHI CHEN, M.D., Ph.D., F.A.C.S.^{1*}

Background: Anterolateral thigh (ALT) flap is now a workhorse flap for reconstruction of skin and soft tissue defects. However, there are some drawbacks in its application, and revisions are often needed after surgery. Here, we present the results of the use of a special type of partition for ALT flap based on the concept of perforator flap vascular anatomy for reconstruction around a protruding structure, a cavity or a canal, in patients. **Patients and methods:** We used the keyhole design for reconstruction with ALT flaps in five patients. Wounds involved circumferential soft tissue defects around the following structures: thumb (two cases), penis, ear canal, and anus. Defects arose following excision of scar contracture, arterio-venous malformation, Paget's disease, squamous cell carcinoma, and Fournier's gangrene, respectively. The ALT flap was raised based on perforators. The flap was partitioned with a keyhole incision performed in a zone between two perforators or distal to them, avoiding complete split of the flap and minimizing disruption of its vascular crossover. The circulation of the flap was well preserved. The closure of the flap had no tension. **Results:** All the flaps had 100% viability without partial loss. Mean follow-up was of 7.4 months (range 4–11 months). Significant functional improvement was achieved in the two thumb cases. Adequate patency of the ear and anal canals was obtained. No contracture around the penis was observed. **Conclusion:** The keyhole design may be a valuable method of partition of the ALT flap for specific reconstructions around protruding organs, cavities, or canals. © 2015 Wiley Periodicals, Inc. *Microsurgery* 35:356–363, 2015.

Since first introduced by Song et al. in 1984,¹ the anterolateral thigh (ALT) flap has gained an immense popularity in reconstructive microsurgery, and contributed to the evolution of perforator flaps. The use of the ALT flap, either as a free or pedicle flap, has been extensively reported in reconstruction of soft tissue defects from head to toe^{2,3}; hence in 2002, Wei et al. defined it as the ideal soft tissue flap.⁴ Its anatomy has been widely studied⁵ and its clinical application is favored for a number of reasons including tremendous versatility, consistent long vascular pedicle, adequate vessel caliber, large flap territory, minor donor site morbidity, ease to design, and possibility to enhance a two-team approach.^{6,7} The thickness of the flap is also adaptable.⁸ Furthermore, it is possible to use it as a sensate or flow-through flap if necessary.^{9,10}

In recent years, numerous modifications of the ALT flap have been described, in an effort to increase its utility and achieve a customized reconstruction of complex soft tissue

defects.¹¹ Supra-fascial dissection and primary thinning techniques have been employed to improve flap contour, and meet the needs of the recipient bed.¹² Based on its vascular anatomy,¹³ the ALT can be also harvested with two or three separate skin paddles or as chimeric flap,¹⁴ with a separate muscle/fascia component.¹⁵ Thus, is ideal in providing flexibility for reconstruction of through-and-through or other composite defects.¹⁶ Its pliability also allows the flap to be folded and shaped as bilobed¹⁷ or cathedral triptych design,¹⁸ as described for tongue reconstruction.

However, despite the evolution in perforator flap surgery and the large number of variations described for the ALT flap, there are still significant drawbacks in its application. These are more apparent when specific anatomical areas are concerned such as protruding organs, cavities, or canals. Reconstruction around such structures with a three-dimensional configuration comprises a real challenge for the microsurgeon and revision procedures are frequently necessary to improve function and cosmesis.

In this article, we introduce the “keyhole” modification for the ALT flap, a technique based on the concept of perforator flap vascular anatomy and present our experience with the keyhole technique in five patients. The advantages and potential limitations of this method in the clinical setting are also discussed.

PATIENTS AND METHODS

From October 2013 to September 2014, we used the keyhole ALT flap in five cases. The patients' details are summarized in Table 1. Defects arose from cancer resection in two cases (ear and penis), Fournier's gangrene in

¹Department of Plastic and Reconstructive Surgery, China Medical University Hospital, Taichung, Taiwan

²Division of Plastic Surgery, Department of Surgery, Faculty of Medicine Vajira Hospital, Navamindradhiraj University, Bangkok, Thailand

³Department of Plastic and Maxillofacial Surgery, Faculty of Medicine Ramathibodi Hospital, Mahidol University, Bangkok, Thailand

⁴Department of Plastic and Reconstructive Surgery, Sapienza University, Rome, Italy

Pornthep Sirimahachaiyakul and Georgios Orfanotis contributed equally to the manuscript.

*Correspondence to: Hung-Chi Chen, M.D., Ph.D., F.A.C.S., 2 Yuh-Der Road, Taichung, Taiwan 40447. E-mail: D19722@mail.cmuh.org.tw

Received 18 September 2014; Revision accepted 15 December 2014; Accepted 19 December 2014

Published online 17 January 2015 in Wiley Online Library (wileyonlinelibrary.com). DOI: 10.1002/micr.22377

Table 1. Summary of Clinical Cases

Case	Age (years)	Sex	Cause of defect	Location of defect	Dimensions of flap (width × length) (cm)		Number of perforators	Donor site closure	Complications	Follow-up (months)	Outcomes
					Pedicle or free flap	Free flap					
1	48	Female	Scar contracture	Left thumb and 1st web space	9 × 15	Free flap	2	Primary	Nil	7	Improved range of motion
2	42	Female	Refractory AVM	Right thumb and 1st web space	8 × 16	Free flap	2	primary	Nil	9	Satisfactory aesthetic outcome with full range of motion
3	78	Male	Squamous cell carcinoma	External ear canal	15 × 15	Free flap	2	Skin graft	Nil	11	Satisfactory
4	75	Male	Paget's disease	Penis and scrotum	15 × 18	Pedicle flap	3	Skin graft	Nil	6	Satisfactory aesthetic outcome without contracture
5	62	Male	Fournier's gangrene	Anal canal and perineum	14 × 17	Pedicle flap	3	Skin graft	Nil	4	Satisfactory with patent anal canal

one case (anus and perineum), release of scar contracture in one case (thumb), and excision of arterio-venous malformation (AVM) in one case (thumb). The keyhole technique was applied in three free and two pedicle (anus and penis) ALT flaps. There were three male and two female patients, with an average age of 61-years old (range from 42 to 78 years old).

Surgical Technique

In each case, careful design of the flap was undertaken following creation of the surgical defect. Adequate recipient vessels were selected and prepared for the three cases of free ALT flap transfer. For the two patients with perineal defects, a pedicle ALT flap was preferred. All flaps were marked with the patient placed in a supine position. A line was drawn from the anterior–superior iliac spine to the supero-lateral border of the patella, to mark the longitudinal axis of the flap. This line corresponded to the inter-muscular septum between the rectus femoris and the vastus lateralis muscles. Mapping of the perforators, originating from the descending branch of the lateral circumflex femoral pedicle, was carried out with the use of a hand-held Doppler device. Accurate flap design according to the dimensions of the defect was facilitated by the use of a sponge template. The desired pedicle length (or the pivot point for the pedicle flaps), along with the position of the keyhole opening, were also anticipated. Subsequently, harvesting of the ALT flap proceeded in standard fashion.¹⁹ Once the perforators were identified, further modifications were made as necessary to include, when possible, at least two perforators in the final flap design.

Following elevation, the ALT flap was transferred to the recipient wound, and revascularization occurred (for the three free transfers). In the two pedicle ALT flap cases, a tunnel was created under sartorius and rectus femoris muscles, to facilitate tensionless advancement to the perineum. Once adequate perfusion was confirmed, the desired location of the keyhole was marked. At this stage, we inspected the position of the perforators under the microscope, to identify a safe zone where an incision could be placed, without compromising the peripheral blood supply (Fig. 1). In three cases, this zone was confined between two perforators whilst in the remaining two, the keyhole fell in a zone distal to them. This occurred due to topographical limitations during flap inset. Following confirmation of the exact position of the aperture, a curvilinear full-thickness incision was performed to accommodate the specific configuration of the organs or cavities. Meticulous thinning was made under the microscope, focusing on the portion of the flap in vicinity to the keyhole. Quilting sutures were also applied to facilitate fixation of the flap around the particular structures. Finally, the flap was inset avoiding

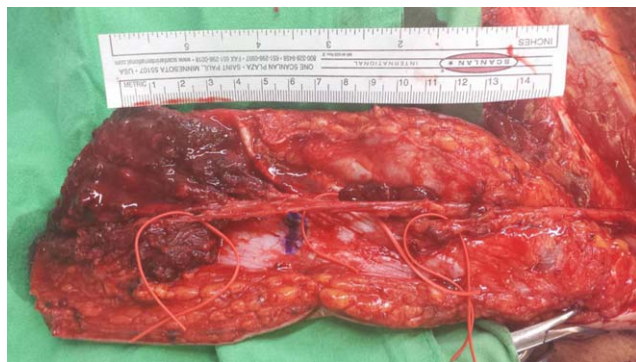


Figure 1. ALT flap was raised on three perforators (red vessel loops). Position of the perforators was inspected under the microscope to identify a safe zone where the keyhole incision could be placed (marked with blue).

tension at the junction with the native tissues, and ensuring that the organ or canal was not constricted within the aperture.

Two ALT flap donor sites were closed primarily whilst three cases required coverage with a split thickness skin graft due to the large ALT flap harvested.

RESULTS

ALT flaps had an average width of 12.2 cm (range 8–15 cm) and an average length of 16.2 cm (range 15–18 cm). The average number of perforators included was 2.4 (range 2–3). There were no events of flap loss or re-exploration. No partial or marginal necrosis was noted. Mean follow-up was of 7.4 months (range from 4 to 11 months). In all cases, the reconstructive aims were achieved. In the two thumb reconstruction cases, the patients showed significant improvement in the range of motion following surgery. No contracture was present in the penial and thumb cases. Adequate patency of the ear and anal canals was obtained. The aesthetic outcome was also satisfactory in all cases. During the follow-up period, no revision surgery was undertaken or planned.

Case Reports

Case 2. A 42-year-old female was referred to our unit with a history of recurrent AVM, involving her dominant right hand, wrist, and proximal forearm. The lesion was refractory to former treatment with embolization and surgery, performed in a different center. Symptoms included severe pain, impairment of hand function, trophic changes, and scar contractures from previous surgery. Due to the severity of these symptoms, the patient opted for radical excision and reconstruction with a free flap. Excision was undertaken under tourniquet control and involved skin and subcutaneous tissue of the radial aspect of palm, 1st web-space, and dorsum of hand and wrist. The resulting defect was circumferential to the

right thumb, which was free of disease (Fig. 2A). The patient underwent a free keyhole ALT flap based on two medium-sized perforators. Flap size measured 8 cm × 16 cm. Microsurgical anastomosis was carried out end-to-end to the proximal stump of the radial artery, and end-to-end to cephalic vein and one vena comitans. The keyhole aperture was created in an area distal to the perforators and the flap was thinned and fashioned to cover the recipient wound. The donor site was closed primarily. There were no immediate or delayed post-operative complications of note and the flap survived fully. At 9 months follow-up, the patient demonstrated excellent hand function with no pain or discomfort and an acceptable aesthetic outcome (Figs. 2B and 2C).

Case 4. A 75-year-old male patient was referred to our unit with recurrent Paget's disease of the scrotum. A wide local excision was carried out involving all the scrotal skin bilaterally and an area of pubic skin around the penial base (Fig. 3A). A pedicle ALT flap measuring 15 cm × 18 cm was raised based on three perforators. A tunnel was created under the sartorius and rectus femoris muscles to facilitate reach of the flap to the defect. The skin over the groin crease was also decompressed using the excess flap tissue, avoiding tension on the pedicle. The keyhole incision was made between the two proximal perforators after defining a safe zone under microscopic magnification. The orientation of the incision was perpendicular to the long axis of the flap to allow better adaptation of the penis. Thinning was performed around the aperture and also on the distal part of the flap, which was used to resurface the testicles (Fig. 3B). Donor site closure was carried out with a split thickness skin graft due to large size of flap needed. No post-operative complications were recorded and the flap has fully survived with a satisfactory clinical outcome. At early post-operative follow-up, the keyhole maintained a good shape with no contracture of the penis (Figs. 3C and 3D). At 6-months follow-up the result remained satisfactory and no revision was required.

Case 5. A 62-year-old diabetic male was acutely admitted in ICU with severe sepsis and a diagnosis of Fournier's gangrene involving the perianal area. The patient underwent three consecutive debridement procedures and treatment with intra-venous antibiotics. A de-functioning colostomy was also performed to facilitate adequate management of the perineal wounds. After satisfactory progress of patient's general condition and wound status, we undertook reconstruction with a pedicle ALT flap. Initially, the wound has been adequately debrided and definite surgical defect was confirmed. The wound involved an area extending from the scrotum to the natal cleft, with circumferential skin deficiency around the anal canal (Fig. 4A). A pedicle ALT flap

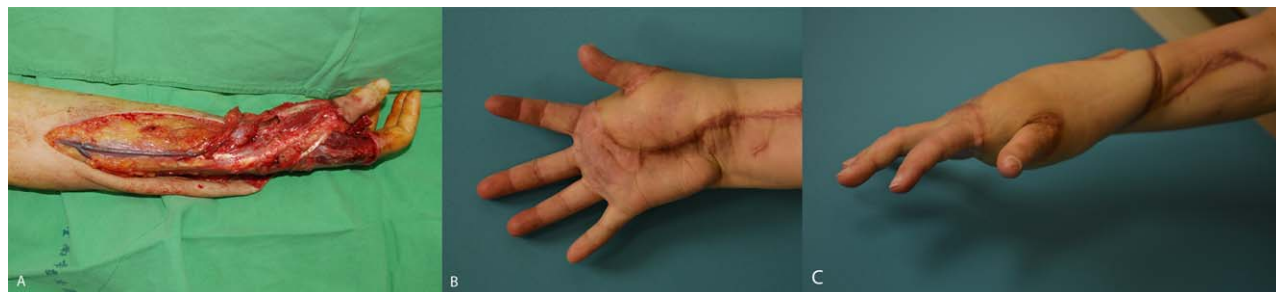

Figure 2. Case 2. **A:** Extensive resection of a refractory AVM on the right hand. Defect involved the radial aspect of palm, 1st web-space, and wrist dorsum of the right hand. **B, C:** Result following reconstruction with a keyhole ALT at 9 months follow-up. Patient showed a good range of motion with no contracture deformity and a satisfactory aesthetic result.

measuring 14 cm × 17 cm was based on three perforators and included a portion of vastus lateralis muscle, to obliterate the dead space in the perineum. A sub-muscular tunnel under rectus femoris and sartorius muscles was created and the skin on the left groin crease was decompressed. The keyhole opening was made through a “U” shaped incision in a safe zone between the two distal perforators (Fig. 4B). Subsequently, the flap was sutured to itself to re-create the perineal raphe and a small skin graft was applied to the scrotum to avoid excessive tension on the flap. No post-operative problems were noted. Total flap survival was achieved and all wounds had fully healed at 3 weeks (Fig. 4C). At 4 months follow-up, the result was satisfactory with adequate patency of the anal canal. A colostomy reversal procedure was planned at 6 months post-operatively.

DISCUSSION

During the last 2 decades, the development of microsurgery allowed flap reconstruction surgery to be performed safer, easier, in less operative time, and with superior results in both the recipient and donor site.²⁰ The evolution of the perforator flaps has had a major contribution in achieving these goals. Nowadays, the ALT flap epitomizes the perforator flap concept, and is well recognized as the workhorse flap in the reconstruction of soft tissue defects in almost every part of the body. A variety of perineal defects arising from oncological resection or necrotizing infections are suitable for coverage with pedicle ALT flaps, alleviating the need for free transfers or pedicled abdominal flaps.^{21–23} It's role in hand and first web-space reconstruction has also been well established.^{24,25} However reconstruction of complex, circumferential defects around thumb, penis, anus, or vagina frequently pose a management dilemma as to whether divide (fully or partially) the ALT flap or use a second flap. We believe the keyhole technique may offer an attractive alternative for reconstruction in these circumstances as we showed in our cases.

A similar modification to the keyhole ALT flap has previously been reported by Zeng et al.²⁶ In this article, the authors described a “fenestrated” technique for pedicled ALT flap. This method was utilized in two patients to reconstruct vulvar defects following cancer resection. In one case, the fenestration was performed on a pedicle ALT flap based on a single perforator. This resulted in significant partial flap necrosis, which subsequently required further coverage with an abdominal flap. The authors here utilized a “Y” shaped incision in the skin paddle, to accommodate the vagina and the urethral meatus. However there was no clarification as to whether the “Y” incision had a direction parallel or perpendicular to the long axis of the flap.

Our report did not include any vulvar reconstruction cases. Compared to the structures we presented (thumb, penis, anus, and external auditory meatus), the dimensions of the vulva are larger. Therefore, when creating the keyhole aperture, incision should be long enough to accommodate both vagina and urethral meatus. We believe such a long “Y” pattern incision carries a significant risk of distal flap loss, specifically when orientated incorrectly on an ALT flap which is based solely on one perforator. None of our patients suffer from partial flap necrosis. However, all flaps were raised based on two or three perforators. In three out of five flaps, the topographic characteristics allowed positioning of keyhole in a safe zone between two perforators. In the remaining two, incision was performed distally, outside the borders of this safe zone. In this event, orientation of the incision was of paramount importance, to minimize disruption of the distal blood supply. This concept has its explanation based on the perforasome theory introduced by Saint-Cyr et al.²⁷ According to this theory, existence of linking vessels between two perforators enables capture of adjacent vascular territories, allowing extended ALT flaps to be harvested based on a single perforator. It has been proved that the direction of the linking vessels in the lower limb runs parallel to the limb axis. Therefore, when an opening incision is made distal to the

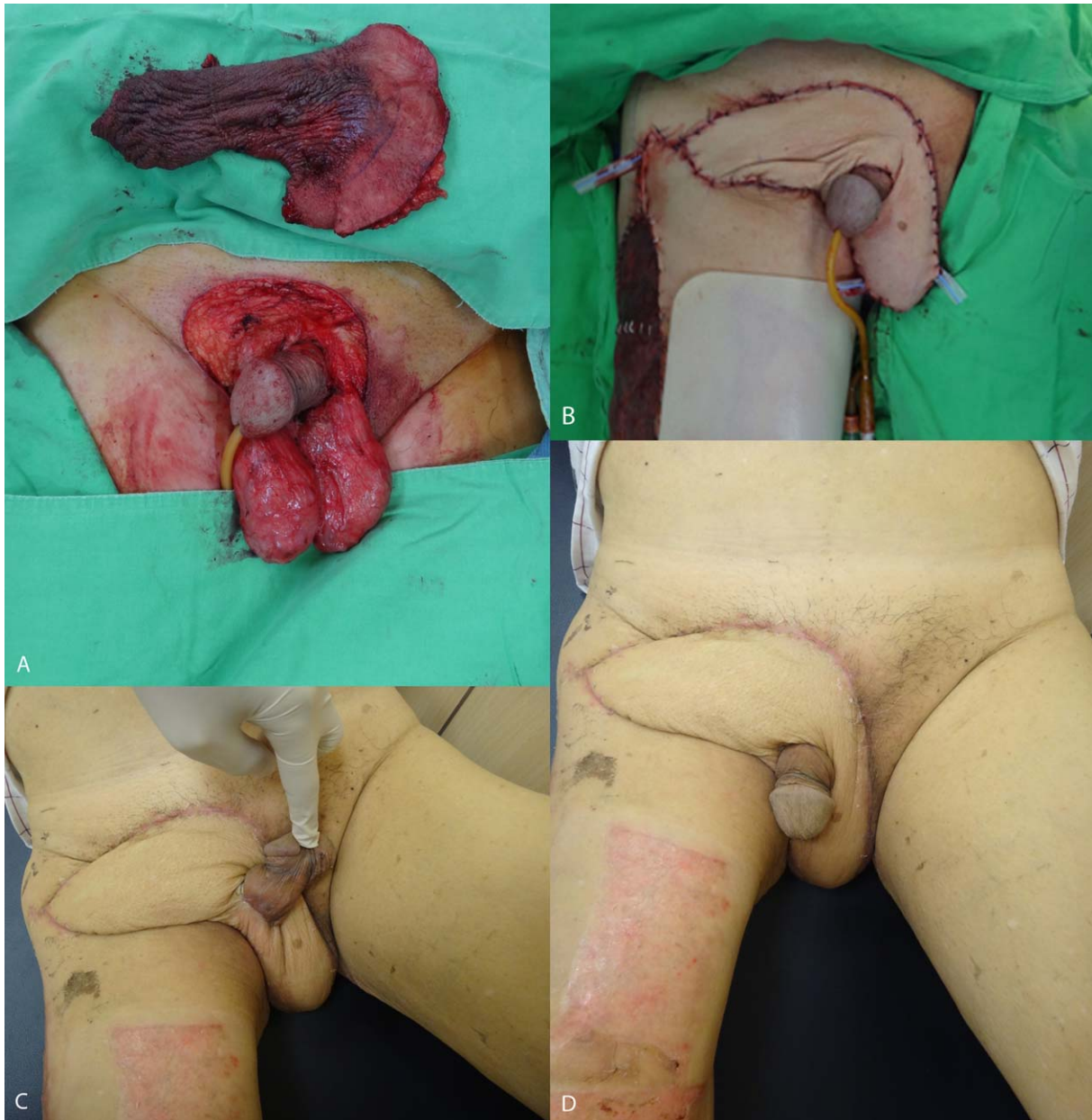


Figure 3. Case 4. **A:** Pubic and perineal defect following wide excision of paget's disease with the resection specimen. **B:** Immediate post-operative picture after reconstruction with keyhole ALT. **C, D:** At 2 months follow-up, pictures showing normal position of the penis, complete coverage of the defect, and no partial necrosis or any signs of contracture.

perforator(s), it should have a direction parallel to the linking vessels (Fig. 5). This will limit disruption of the peripheral flap vasculature and maximize flap survival. Based on this consideration, we believe the keyhole technique can still be applied safely, even in flaps where a single midline perforator is encountered (Fig. 6). However, when a single perforator is located at the extreme lateral margins of the flap, there would be limited crossover between the vascular zones. In this rare scenario, a keyhole incision could cause potential vascular embar-

rassment and hence should be avoided. Here, complete wound coverage around the particular structure could be aided by the means of local tissue, if available, or by simply folding the flap around the area avoiding any tension. The resulting unfavorable reconstructive outcome could be improved with secondary revision procedure(s).

In recent years, the use of computed tomography angiogram (CTA) has offered a number of advantages in breast reconstruction with free deep inferior epigastric perforator (DIEP) flaps.²⁸ Pre-operative mapping of the

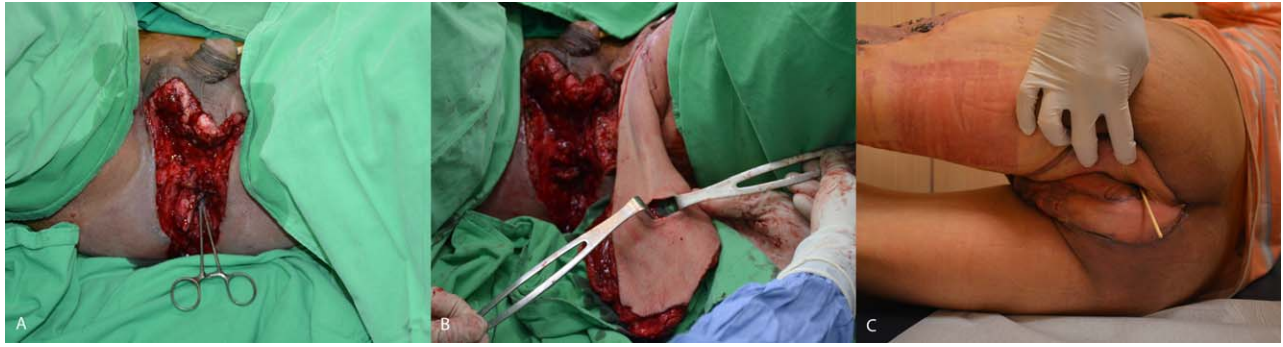


Figure 4. Case 5. **A:** Extensive perineal defect following definitive debridement of Fournier's gangrene. Defect involved the area between the scrotum and the natal cleft, with circumferential skin deficiency around the anal canal (indicated with a clamp). **B:** A "U" shaped incision was made for the keyhole opening in a safe zone between the two distal perforators. **C:** Follow-up at 3 weeks showing a satisfactory contour and adequate patency of the anal canal (indicated with the cotton bud).

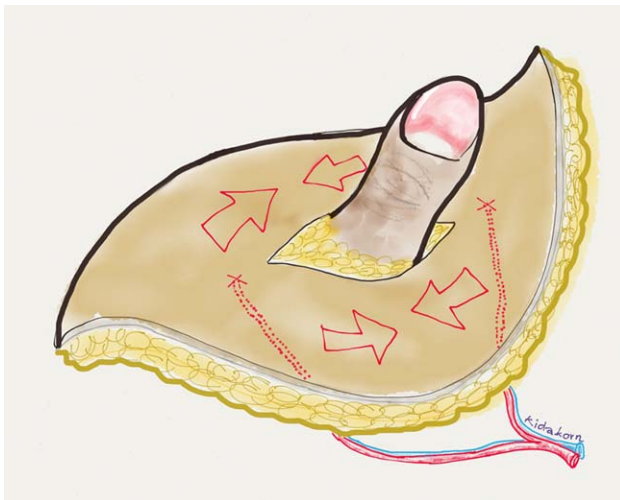


Figure 5. Keyhole incision was performed in a safe zone between two perforators. The arrows indicated the direction of the direct linking vessels between two perforasomes, which were preserved, allowing complete flap survival.

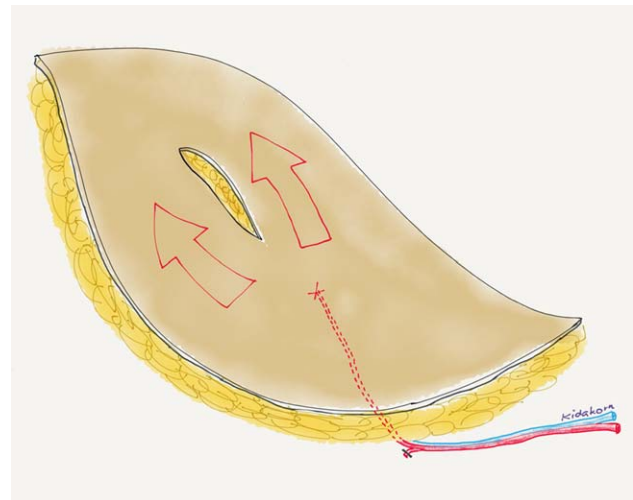


Figure 6. Illustration showed an ALT flap based on a single perforator. The keyhole incision should be made longitudinal to the long axis of the flap to minimize disruption of the direct linking vessels. The same concept can be applied for ALT flap based on [mt]1 perforator in which a keyhole incision is placed distal to the perforators.

perforators not only increases the success rates of the procedure, but also reduces the operative time. Although in our report we did not use CTA in any of our cases, we believe that pre-operative mapping of the ALT flap perforators will allow a more accurate and safer planning of the keyhole design. Moreover, CTA could be particularly useful in those patients with microcirculation problems (diabetics, heavy smokers, or those with irradiated recipient vessels), specifically when large ALT flaps are planned. Here, pre-operative confirmation of the location and quantity of the thigh perforators will clarify whether these patients would be suitable for reconstruction with a keyhole ALT flap.

An alternative to the keyhole technique is the partial or total split-ALT flap modification, as described by pre-

vious authors.^{29,30} We have also previously used this approach in our unit while reconstructing protruding structures or cavities. However, division of the ALT flap in two separate skin paddles can only be performed in the zone between two perforators and not distal to them, and thus this technique was not applicable in two of our cases. Moreover, even when applicable, we found the split methods to be unpredictable and potentially hazardous to the flap supply. Here, damage of the linking vessels between two adjacent perforasomes frequently resulted in significant impairment of the marginal blood supply and partial flap loss (Fig. 7).

When partial flap necrosis occurs, a wide range of complications can arise, depending on the extent of tissue

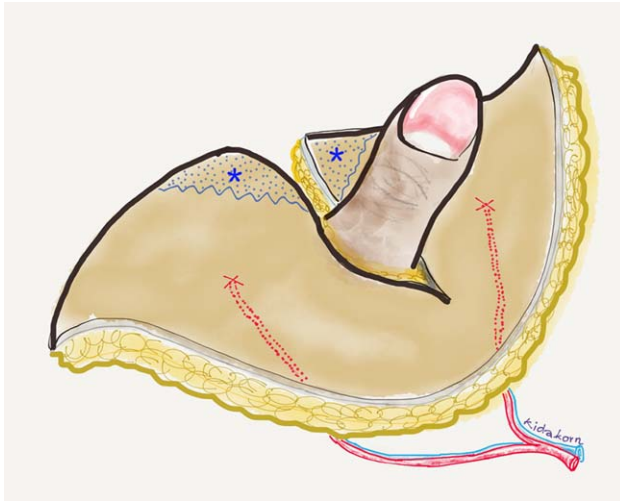


Figure 7. Division of ALT flap between proximal and distal perforators carried a risk of marginal flap necrosis (indicated by the star areas).

loss and the anatomical area concerned. Substantial flap necrosis is most commonly managed with debridement procedure(s) and may even entail the need for further reconstruction with skin graft or a second flap.³¹ This eventually leads to suboptimal outcome and prolonged hospital stay. Although conservative management of limited necrotic areas is possible in selected cases, resulting delayed healing can lead to secondary scar contractures and possible need for revision surgery. This is especially true in cases of hand reconstruction, where early mobilization is essential to achieve the reconstructive goals.³² In fact, obtaining primary healing was of extreme importance in the two thumb reconstruction cases in our series. This allowed hand physiotherapy to commence at an early post-operative stage. At follow-up both patients demonstrated a satisfactory range of motion including significant improvement in thumb abduction and opposition. Application of the keyhole technique in these circumstances offers the advantage of covering with pliable and reliable, well-vascularized tissue an area susceptible to early contracture. In addition, we observed that this method offers more natural results in aesthetically sensitive areas. In case 5, flap inset around the anus was carried out in a method similar to the technique described by Niranjana and Staiano for re-setting the umbilicus in abdominoplasty.³³ This method offered a more natural-looking depression and created fullness around the anus to permit its natural mobility. Meticulous thinning around the keyhole can be performed safely and allows better adaptation and fixation around the particular structures. Furthermore, avoidance of additional splitting incisions and scarring has also contributed toward a superior aesthetic outcome.

In summary, here we present the keyhole modification, a special way of partition for the ALT flap. We

believe this technique may offer a valuable alternative for soft tissue coverage around protruding organs, cavities, or canals. To the best of our knowledge, the keyhole technique has not been previously described for reconstruction of the specific structures included in this study. The basis of this method lies on the perforator vascular supply principle, and as such, it could be also applied to different perforator flaps, whenever indicated.

REFERENCES

1. Song YG, Chen GZ, Song YL. The free thigh flap: A new free flap concept based on the septocutaneous artery. *Br J Plast Surg* 1984; 37:149–159.
2. Zhang B, Wan JH, Wan HF, Li DZ, Zhan YX. Free perforator flap transfer for reconstruction of skull base defects after resection of advanced recurrent tumor. *Microsurgery* 2014;34:623–628.
3. Lin PY, Miguel R, Chew KY, Kuo YR, Yang JC. The role of the anterolateral thigh flap in complex defects of the scalp and cranium. *Microsurgery* 2014;34:14–19.
4. Wei FC, Jain V, Celik N, Chen HC, Chuang DC, Lin CH. Have we found an ideal soft-tissue flap? An experience with 672 anterolateral thigh flaps. *Plast Reconstr Surg* 2002;109:2219–2226; discussion 2227–2230.
5. Rozen WM, Ashton MW, Pan WR, Kiil BJ, McClure VK, Grinsell D, Stella DL, Corlett RJ. Anatomical variations in the harvest of anterolateral thigh flap perforators: A cadaveric and clinical study. *Microsurgery* 2009;29:16–23.
6. Chen HC, Tang YB. Anterolateral thigh flap: An ideal soft tissue flap. *Clin Plast Surg* 2003;30:383–401.
7. Hanasono MM, Skoracki RJ, Yu P. A prospective study of donor-site morbidity after anterolateral thigh fasciocutaneous and myocutaneous free flap harvest in 220 patients. *Plast Reconstr Surg* 2010; 125:209–214.
8. Ohjimi H, Taniguchi Y, Kawano K, Kinoshita K, Manabe T. A comparison of thinning and conventional free-flap transfers to the lower extremity. *Plast Reconstr Surg* 2000;105:558–566.
9. Kimata Y, Uchiyama K, Ebihara S, Kishimoto S, Asai M, Saikawa M, Ohyama W, Haneda T, Hayashi R, Onitsuka T, Nakatsuka T, Harii K. Comparison of innervated and noninnervated free flaps in oral reconstruction. *Plast Reconstr Surg* 1999;104:1307–1313.
10. Ao M, Nagase Y, Mae O, Namba Y. Reconstruction of posttraumatic defects of the foot by flow-through anterolateral or anteromedial thigh flaps with preservation of posterior tibial vessels. *Ann Plast Surg* 1997;38:598–603.
11. Engel H, Gazyakan E, Cheng MH, Piel D, Germann G, Giessler G. Customized reconstruction with the free anterolateral thigh perforator flap. *Microsurgery* 2008;28:489–494.
12. Kimura N, Satoh K. Consideration of a thin flap as an entity and clinical applications of the thin anterolateral thigh flap. *Plast Reconstr Surg* 1996;97:985–992.
13. Lakhiani C, Lee MR, Saint-Cyr M. Vascular anatomy of the anterolateral thigh flap: A systematic review. *Plast Reconstr Surg* 2012; 130:1254–1268.
14. Jiang C, Guo F, Li N, Huang P, Jian X, Munnee K. Tripaddled anterolateral thigh flap for simultaneous reconstruction of bilateral buccal defects after buccal cancer ablation and severe oral submucous fibrosis release: A case report. *Microsurgery* 2013;33:667–671.
15. Peng F, Chen L, Han D, Xiao C, Bao Q, Wang T. Reconstruction of two separate defects in the upper extremity using anterolateral thigh chimeric flap. *Microsurgery* 2013;33:631–637.
16. Sun G, Lu M, Hu Q, Tang E. Reconstruction of extensive through-and-through cheek defects with free anterolateral thigh flap. *J Craniofac Surg* 2014; 25:e31–e38.

17. Longo B, Ferri G, Fiorillo A, Rubino C, Santanelli F. Bilobed perforator free flaps for combined hemitongue and floor-of-the-mouth defects. *J Plast Reconstr Aesthet Surg* 2013; 66:1464–1469.
18. Leymarie N, Karsenti G, Sarfati B, Rimareix F, Kolb F. Modification of flap design for total mobile tongue reconstruction using a sensitive antero-lateral thigh flap. *J Plast Reconstr Aesthet Surg* 2012; 65:e169–e174.
19. Saint-Cyr M, Oni G, Lee M, Yi C, Colohan SM. Simple approach to harvest of the anterolateral thigh flap. *Plast Reconstr Surg* 2012; 129:207–211.
20. Townley WA, Royston EC, Karmiris N, Crick A, Dunn RL. Critical assessment of the anterolateral thigh flap donor site. *J Plast Reconstr Aesthet Surg* 2011;64:1621–1626.
21. Chen SY, Fu JP, Chen TM, Chen SG. Reconstruction of scrotal and perineal defects in fourier's gangrene. *J Plast Reconstr Aesthet Surg* 2011;64:528–534.
22. Yu P, Sanger JR, Matloub HS, Gosain A, Larson D. Anterolateral thigh fasciocutaneous island flaps in perineoscrotal reconstruction. *Plast Reconstr Surg* 2002;109:610–616.
23. Spyropoulou GA, Jeng SF, Demiri E, Dionyssopoulos A, Feng KM. Reconstruction of perineoscrotal and vaginal defects with pedicled anterolateral thigh flap. *Urology* 2013;82:461–465.
24. Adani R, Tarallo L, Marcoccio I, Fregni U. First web-space reconstruction by the anterolateral thigh flap. *J Hand Surg Am* 2006;31: 640–646.
25. Chen HC, Tang YB, Mardini S, Tsai BW. Reconstruction of the hand and upper limb with free flaps based on musculocutaneous perforators. *Microsurgery* 2004;24:270–280.
26. Zeng A, Qiao Q, Zhao R, Song K, Long X. Anterolateral thigh flap-based reconstruction for oncologic vulvar defects. *Plast Reconstr Surg* 2011;127:1939–1945.
27. Saint-Cyr M, Wong C, Schaverien M, Mojallal A, Rohrich RJ. The perforasome theory: Vascular anatomy and clinical implications. *Plast Reconstr Surg* 2009;124:1529–1544.
28. Teunis T, Heerma van Voss MR, Kon M, van Maurik JF. CT-angiography prior to DIEP flap breast reconstruction: A systematic review and meta-analysis. *Microsurgery* 2013;33:496–502.
29. Chang NJ, Waughlock N, Kao D, Lin CH, Lin CH, Hsu CC. Efficient design of split anterolateral thigh flap in extremity reconstruction. *Plast Reconstr Surg* 2011;128:1242–1249.
30. Filobos G, Chapman T, Khan U. Split anterolateral thigh (ALT) free flap for vulva reconstruction: A case report. *J Plast Reconstr Aesthet Surg* 2012;65:525–526.
31. Hallock GG. Partial failure of a perforator free flap can be salvaged by a second perforator free flap. *Microsurgery* 2014;34:177–182.
32. King EA, Ozer K. Free skin flap coverage of the upper extremity. *Hand Clin* 2014;30:201–209.
33. Niranjan NS, Staiano JJ. An anatomical method for re-siting the umbilicus. *Plast Reconstr Surg* 2004;113:2194–2198.